

The Diagnostic Value of Transthoracic Ultrasonographic Features in Predicting Malignancy in Undiagnosed Pleural Effusions: A Prospective Observational Study

Antonio Bugalho^{a, c, d} Dalila Ferreira^c Sara S. Dias^{a, b} Maren Schuhmann^f
Jose C. Branco^e Maria J. Marques Gomes^a Ralf Eberhardt^f

^aChronic Diseases Research Center (CEDOC) and ^bDepartamento Universitário de Saúde Pública, Faculdade de Ciências Médicas, Universidade Nova de Lisboa, and ^cInterventional Pulmonology Unit, Centro Hospitalar Lisboa Norte, Hospital Pulido Valente, Lisbon, and ^dInterventional Pulmonology Unit and ^eImagiology Department, Hospital Beatriz Angelo, Loures, Portugal; ^fPneumology and Critical Care Medicine Department, Thoraxklinik, University of Heidelberg, Heidelberg, Germany

For editorial comment see p. 265

Key Words

Ultrasound · Thorax · Pleural effusion · Diagnosis · Lung cancer · Neoplasia

Abstract

Background: Transthoracic ultrasound (US) is an important instrument to identify pleural effusions and safely conduct invasive procedures. It also allows systematic scanning of the pleural surface, though its value remains uncertain for differentiation between malignant (MPE) and nonmalignant pleural effusion (non-MPE) in routine clinical practice. **Objectives:** To evaluate the utility of US features to predict malignancy in undiagnosed pleural effusions in a real-life clinical setting. **Methods:** The US features of 154 consecutive patients with a pleural effusion were prospectively assessed. Anonymous images were recorded by an operator blinded to the clinical and radiological results. The US findings were classified by independent reviewers and compared to the final diagnosis. **Results:** A total of 133 patients were included (age 67 ± 16 years; BMI 25.1 ± 4.6 ; 54.1% females). The final diagnosis was MPE in 66 cases and non-MPE in 67 cases. US had an overall sensitivity of 80.3%, a specificity of 83.6%, and

positive and negative predictive values of 82.8 and 81.2%, respectively, for the detection of malignancy. US accuracy was 81.9%. The presence of pleural/diaphragmatic nodules, pleural/diaphragmatic thickness >10 mm, and a swirling sign was significantly different between both groups ($p < 0.001$). Lung air bronchogram sign and a septated US pattern were more common in non-MPE patients ($p < 0.01$). The existence of nodularity and the absence of air bronchograms were more likely to indicate malignancy (OR 29.0, 95% CI 7.65–110.08 and OR 10.4, 95% CI 1.65–65.752, respectively). **Conclusions:** In the presence of an undiagnosed pleural effusion, US morphological characteristics can aid in differentiating MPE from non-MPE. Pleural/diaphragmatic nodularity was the most relevant feature although no finding was pathognomonic of MPE.

© 2014 S. Karger AG, Basel

Introduction

Malignant involvement of the pleura is a common clinical condition and a frequent cause of pleural effusions [1]. Virtually all tumors may disseminate cancer

cells and cause pleural deposits, disrupting the physiological pleural fluid turnover. Lung cancer is responsible for one third of pleural effusions, with a median survival of 8–10 months [2]. Regardless of the underlying neoplasm, a malignant pleural effusion (MPE) indicates advanced disease and a poor prognosis; thus, prompt diagnosis is essential to accurately stage the patient and initiate adequate treatment.

An undiagnosed pleural effusion requires a clinical evaluation along with complementary imaging studies and minimally invasive procedures to establish its etiology. Cytological evaluation of the first pleural fluid sample has a mean sensitivity for malignancy of 62% and collection of a second specimen is able to increase the diagnostic yield to about 72% (total range 49–91%) [3]. Due to its variable sensitivity, international guidelines state that if pleural fluid cytology fails to provide a definitive diagnosis and malignant disease is suspected, image-guided pleural biopsy or thoracoscopy is a subsequent step to determine the underlying cause of the effusion [3, 4]. These procedures are more invasive compared to thoracentesis; therefore, prior examinations are fundamental to effectively select patients.

In the evaluation of a likely MPE, thoracic computed tomography (CT) plays an important role in planning the adequate diagnostic strategy since it permits assessment of the pleural surface, lung, and metastatic disease simultaneously and with great detail. However, CT is not a real-time exam and it is associated with radiation exposure and cannot reliably exclude malignant pleural disease [5, 6].

Chest ultrasound (US) is a simple, effective, and inexpensive exam that is widely available and increasingly accessible to the pulmonologist [7, 8]. There is substantial scientific evidence concerning the importance of this technique in detecting pleural effusions and guiding thoracentesis as it increases the diagnostic yield and diminishes complications, especially in small and septated effusions [4]. In addition, US is able to identify pleural lesions and provide real-time control for percutaneous pleural biopsies, reducing the rate of false-negative punctures [8–10]. It has been reported that chest US performed by expert radiologists, in a controlled population after exclusion of pleural infection, may be useful to predict pleural malignancy which might allow successful triage of patients for additional diagnostic procedures [11]. However, there is limited information regarding the importance of sonographic features to distinguish MPE from nonmalignant effusions (non-MPE) in routine clinical practice. Further-

more, the published studies have taken place in countries with a low incidence of tuberculosis. The incidence of tuberculosis in our local population is reported to be 21.6 cases per 100,000 inhabitants and this condition may cause additional difficulties in differential diagnosis.

Finally, data about the efficacy of this exam performed by respiratory physicians in unselected patients is lacking.

This prospective study was designed to assess the value of thoracic US, performed by nonradiologists, for detecting malignancy in patients with an undiagnosed pleural effusion. Moreover, we aimed to determine which individual or combined US characteristics better discriminate between MPE and non-MPE.

Material and Methods

Study Population

All consecutive patients referred for assessment of a presumed pleural effusion over an 11-month period (February to December 2011) were included in this study. The inclusion criteria were as follows: (1) age ≥ 18 years and (2) a suspected undiagnosed pleural effusion on a recent chest X-ray (< 7 days). Patients were excluded based on: (1) the absence of a pleural effusion at the time the US procedure was performed, (2) the presence of a pleural effusion of known etiology, (3) bilateral effusions strongly suggestive of a transudate responsive to medical treatment in the first 48 h, (4) previous pleural manipulation (e.g. thoracic surgery), (5) contraindications for thoracentesis, or (6) refusal to participate in the study.

This study was approved by the Centro Hospitalar Lisboa Norte ethics committee and all participants gave written informed consent prior to participation.

Transthoracic US Procedures and Recorded Features

The US evaluations were performed using ACUSON X300 equipment (Siemens, Germany) by a respiratory physician with at least 5 years of thoracic US experience (average of 450 exams/year) trained according to the recommendations of The Royal College of Radiologists [12].

A nurse placed the patient in an upright sitting position with arms crossed resting on a bedside support table. In some cases, due to patient limitations, lateral decubitus positions were used. The US operator had no information regarding the medical records of the patient or previous radiological examinations. For sonographic scanning of the pleura, effusion, and lung, a 2- to 5-MHz convex-array probe was used. Details of the thoracic wall and parietal pleura were visualized with a 5- to 10-MHz linear-array transducer. Both hemithoraces were scanned systematically. The transducer was moved from dorsal to ventral positions and from the diaphragm to the apex along the thoracic longitudinal lines and through the intercostal spaces along the rib axis in order to locate anatomical landmarks and pathological features [13]. Color flow Doppler was used to assess the presence of

vascular structures and diagnose minimal or loculated pleural effusions.

During each US examination the following characteristics were documented: patient position; scanning duration; pleural effusion side (left, right, or bilateral) and size (small, moderate, or large classified as less than one third, more than one third but less than two thirds, or greater than two thirds of the hemithorax, respectively); sonographic pattern of the effusion (anechoic, heterogeneous echogenic, homogeneous echogenic, or septated) [14]; swirling sign, defined as floating echogenic particles with circular movements within the effusion (present or absent); parietal and visceral pleural thickness; diaphragmatic thickness; pleural and diaphragmatic nodules (present or absent), and other features (lung air bronchogram sign, lung parenchymal lesions, rib/chest wall invasion, and hepatic metastasis).

Relevant static images and 10- to 20-second digital video clips were generated for each patient and catalogued with a code number. These were reviewed by at least 3 different independent sonographers with a level of expertise similar to that of the US operator. Individual sonographic findings were recorded and all cases were classified as high versus low probability of malignancy by each of the sonographers. High probability of malignancy was defined by the presence of at least one of the following parameters: (1) pleural/diaphragm nodules, (2) pleural/diaphragm thickening >10 mm, (3) an adjacent solid pulmonary lesion, and (4) hepatic metastasis [11]. If the interpretations differed, the final sonographic feature and diagnosis was established by the majority.

Final Diagnosis

The diagnostic approach followed the British Thoracic Society guidelines algorithm [4]. After US identification of a pleural effusion, thoracentesis was performed with a fine-bore catheter. The sample was sent for lactate dehydrogenase, protein, glucose, and adenosine deaminase analysis, differential cell count, pH, microbiological analysis (including direct and cultural mycobacterium tuberculosis exams), and cytology. In selected cases a percutaneous US-guided pleural biopsy (Abrams' needle or Tru-Cut needle) was performed to collect specimens from the parietal pleura. A final diagnosis was made based on chemical, microbiologic, cytological, or histological results. MPE and non-MPE diagnoses were managed accordingly and follow-up was maintained for at least 15 months to confirm a consistent clinical course. If a definite diagnosis could not be reached and there was reappearance of the effusion, thoracoscopy or thoracotomy was considered as a further diagnostic option. In case of absence of recurrence of the pleural effusion, the patient underwent clinical, radiological, and US follow-up also during a 15-month period. If malignancy was later diagnosed, the initial nondiagnostic US exam was considered to be false negative.

Statistical Analysis

Data analysis was done with the SPSS 18.0 software package (Chicago, Ill., USA). US characteristics were compared with the final diagnosis. Sensitivity, specificity, accuracy, positive predictive values, and negative predictive values were calculated using the standard formulas. Values were expressed as means \pm SD, frequencies, or percentages. $p < 0.05$ was considered statistically significant. Comparisons between 2 groups were performed using χ^2 tests and logistic regression was used to identify independent predictive factors for malignancy.

Table 1. Characteristics of the study population

Characteristics	Values
Patients, n	133
Female/male ratio	72/61
Mean age (range), years	67 \pm 16 (18–96)
Mean BMI (range), kg/m ²	25.1 \pm 4.6 (15.6–36.4)
<i>Effusion side (X-ray)</i>	
Left	61
Right	57
Bilateral	15
<i>Effusion size^a (X-ray)</i>	
Small (<one third of an hemithorax)	50
Moderate (\geq one third but <two thirds of an hemithorax)	68
Large (\geq two thirds of an hemithorax)	15
<i>Final diagnosis</i>	
Malignant	66
Lung cancer	45
Adenocarcinoma	29
Squamous cell carcinoma	6
Small cell lung cancer	6
Non-small cell lung cancer	4
Mesothelioma	2
Lymphoma	4
Breast cancer	4
Gastrointestinal cancer	6
Other malignancies	5
Nonmalignant	67
Pneumonia	26
Tuberculosis	15
Congestive cardiac failure	11
Hepatic disease	5
Renal failure	3
Pulmonary thromboembolism	2
Nonspecific pleural effusion	5

^a For bilateral pleural effusions the biggest size was considered.

Results

Population Characteristics

During the recruitment period a total of 154 consecutive patients with a suspected pleural effusion of unknown origin were enrolled into this study. Nineteen patients were excluded based on the described criteria and 2 patients were lost to follow-up. The characteristics and final diagnosis of the 133 patients included are summarized in table 1. The duration of pleural effusion symptoms ranged from 5 days to 7 months before patients were sent for diagnosis. In the MPE group the mean delay until presentation was 56 days. All patients

Table 2. Transthoracic US features for malignant and nonmalignant effusions

US features	Malignant effusion (n = 66)	Nonmalignant effusion (n = 67)	Significant p value
Effusion side			
Left	32	29	
Right	32	32	
Bilateral	2	6	
Effusion size			
Small (<one third of an hemithorax)	24	35	
Moderate (≥one third but <two thirds of an hemithorax)	35	28	
Large (≥two thirds of an hemithorax)	7	4	
Effusion echogenicity			
Anechoic	3	19	0.004
Heterogeneous echogenic	53	29	<0.001
Homogeneous echogenic	5	2	
Septated	5	17	0.006
Swirling sign	38	10	<0.001
Thickness ^a (total/>10 mm)	49/49	23/9	<0.001 ^b
Visceral pleura (>3/>10 mm)	34/29	13/7	
Parietal pleura (>3/>10 mm)	16/13	10/2	
Diaphragm (>7/>10 mm)	30/21	14/2	
Total nodularity ^a	52	6	<0.001
Visceral pleura	29	5	
Parietal pleura	17	2	
Diaphragm	36	4	
Lung air bronchogram sign	5	21	0.001
Chest wall invasion	2	0	
Peripheral parenchymal lung lesion	9	0	
Hepatic metastasis	4	0	

Values are presented as numbers unless otherwise stated. ^a Absolute number of patients with pleural or diaphragmatic abnormalities, although some cases had multiple locations that were concurrently involved, as detailed in the rows below and in Results. ^b Refers to a pleural or diaphragmatic thickness >10 mm.

underwent US-guided thoracentesis without any complications.

The final diagnosis was MPE in 66 patients (49.6%) and non-MPE in 67 patients (50.4%). In the first group, 45 patients (33.8%) had lung cancer, 2 (1.5%) had mesothelioma, 4 (3.0%) had lymphoma, 4 (3.0%) had breast cancer, 6 (4.5%) had gastrointestinal cancer (gastric, n = 2; colon, n = 2; hepatobiliary, n = 2) and 5 (3.8%) had other malignancies (renal, n = 1; prostate, n = 2; ovarian, n = 1; thymic, n = 1). The definitive malignant diagnosis was obtained by fluid cytology in 34 cases (51.5%), percutaneous pleural histology in 12 cases (18.2%), thoracoscopic pleural biopsy in 9 cases (13.6%), and other techniques in 11 cases (16.7%). In non-MPE the most common diagnoses were pneumonia in 26 patients (19.5%), tuberculosis in 15 patients (11.2%) (mean adenosine deaminase value 76 ± 29 U/l), and congestive cardiac failure

in 11 patients (8.3%). Five patients (3.8%) remained without a specific diagnosis and without effusion recurrence during the 15-month follow-up. According to Light's criteria 24 (18%) effusions were classified as transudates (2 in the malignant group) and 109 (82%) as exudates.

Of note, 69 patients (51.9%) had a thoracic CT before the US examination and 22 (16.5%) had the referred exam scheduled for the following 3 days.

Transthoracic US Findings

One hundred sixteen patients (87.2%) underwent the US exam sitting upright and 17 (12.8%) were in recumbent positions. The average duration of the US examinations was 18 ± 13 min. Table 2 outlines the US features of MPE and non-MPE. Of the 4 non-MPE occupying more than two thirds of a hemithorax, 3 cases were due to tuberculosis and 1 case was due to pneumonia. There was no

Table 3. Discrimination of thickening and nodularity features for malignant and nonmalignant effusions

Thickening and nodularity findings	Malignant effusion	Nonmalignant effusion
<i>Thickening</i>		
Visceral pleura	10	Pneumonia (n = 3), tuberculosis (n = 1)
Parietal pleura	5	Tuberculosis (n = 2)
Diaphragm	8	Tuberculosis (n = 3), pneumonia (n = 2)
Visceral plus parietal pleura	4	Pneumonia (n = 3)
Visceral pleura plus diaphragm	15	Tuberculosis (n = 3), pneumonia (n = 1)
Parietal pleura plus diaphragm	2	Pneumonia (n = 3)
All locations	5	Tuberculosis (n = 2)
<i>Nodularity</i>		
Visceral pleura	8	Tuberculosis (n = 2)
Parietal pleura	4	n = 0
Diaphragm	13	Tuberculosis (n = 1)
Visceral plus parietal pleura	2	Tuberculosis (n = 2)
Visceral pleura plus diaphragm	12	n = 0
Parietal pleura plus diaphragm	4	Tuberculosis (n = 1)
All locations	7	n = 0

particular predominance concerning the size or side of the effusion in relation to MPE versus non-MPE groups.

In 80.4% of the cases, the MPE was heterogeneous echogenic and in non-MPE the most common US pattern was heterogeneous (43.3%), followed by anechoic (28.3%) and septated (25.4%). In non-MPE the complex septated pattern was associated with exudates such as tuberculosis (n = 9) and complicated pneumonia (n = 8).

The swirling sign was present in a total of 48 cases (36.1%); of these, 38 (28.6%) occurred in malignancy versus 10 (7.5%) in non-MPE ($p < 0.001$). All non-MPE cases with positive swirling signs were exudates associated with tuberculosis or pneumonia.

With regard to pleural or diaphragmatic thickening, a total of 49 patients had >10 mm thickness in the malignant group (74.2%) (table 3). In the non-MPE group 23 patients (34.3%) had pleural or diaphragmatic increased thickness but only 9 had a thickness of >10 mm. All cases of non-MPE thickness were related to infectious diseases. Pleural or diaphragmatic nodularity occurred in 52 patients in the MPE group (78.8%) (fig. 1) and in 6 tuberculosis cases in the non-MPE group (8.9%). The US lung air bronchogram sign was present in 21 patients (15.8%) in the non-MPE group (fig. 1) and 5 patients (3.8%) in the MPE group.

In 4 cases (3.0%) liver metastases were detected during the US exam (primary lung cancer, n = 1; extrathoracic malignancies, n = 3). Nine patients (6.8%) had a distinct homogeneous hypoechoic peripheral tumor with a hyperechoic halo and in 2 cases (1.5%) there was chest wall invasion and absence of a lung gliding sign.

The diagnostic yields for US features are reported in table 4. Thoracic US had an overall sensitivity of 80.3%, a specificity of 83.6%, a positive predictive value of 82.8%, and a negative predictive value of 81.2% for the diagnosis of malignancy. The exam accuracy was 81.9% and the cancer prevalence was 49.6%.

The variables that were predictive of malignancy are listed in table 5. Logistic regression analysis revealed that in the presence of pleural/diaphragmatic nodularity and the absence of lung air bronchogram signs the effusions were more likely to be malignant (OR 29.0, 95% CI 7.650–110.083 and OR 10.416, 95% CI 1.650–65.752, respectively). Other US features, such as the presence of a heterogeneous echogenic pattern, a positive swirling sign, or the absence of a septated pattern, were not predictive of cancer. Diaphragmatic thickness >10 mm was associated with an elevated risk of malignancy (OR 5.351, 95% CI 0.899–31.848) although it was not statistically significant at the 5% level.

Discussion

Pleural effusions are quite common and may occur due to numerous systemic and local diseases. The high incidence of MPE is related to the increasing cancer burden worldwide and lung cancer is one of its leading causes. This study also confirms that MPE are often caused by lung cancer (45 of 66 cases) and, as expected, adenocarcinoma was the most frequent histological type. Due to a worse prognosis compared to the other T4 descriptors, MPE has been upstaged to an M1a disease in the seventh TNM staging system [2] and palliative treatment is usually the main therapeutic option. It is therefore necessary to accurately and quickly differentiate between malignant and benign effusions. Our data shows that in the presence of an undiagnosed effusion US features are able to predict pleural malignancy.

Published studies have proven that in about 40% of cases pleural fluid cytology alone is not able to establish an MPE diagnosis [15–18]. In the present study, the diagnostic rate of pleural fluid cytology for malignancy was 51.5% and the addition of percutaneous biopsy increased the yield by 18.2%, which is consistent with pub-

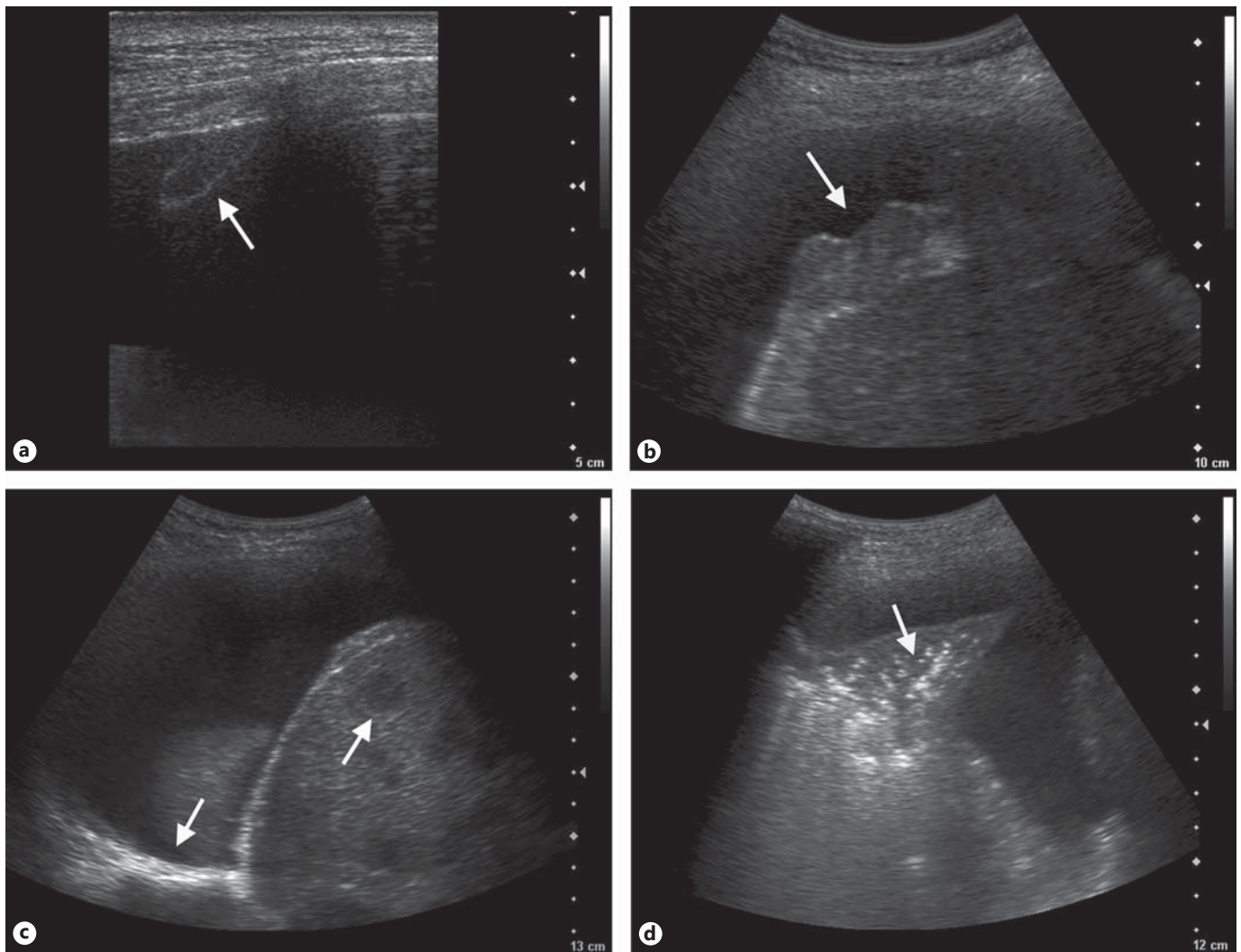


Fig. 1. Transthoracic US features in MPE and benign pleural effusions. **a** Parietal pleural deposit (arrow) surrounded by an anechoic pleural effusion in a 67-year-old man with metastatic squamous cell lung cancer. **b** Nodular thickening of the diaphragmatic pleura (arrow) in a 60-year-old man with renal cell carcinoma pleural metastasis. **c** Right-sided pleural effusion with increased visceral

pleural thickness (arrow), multiple hypoechoic hepatic metastasis (arrow), and irregular diaphragmatic pleura in a 45-year-old woman with lung adenocarcinoma. **d** Linear and tree-shaped hyper-echoic reflexes (arrow) in a 59-year-old man with parapneumonic pleural effusion.

lished data [4]. In order to make a definitive diagnosis, some patients have to be subjected to more invasive tests, but even after an extensive workup a small number of pleural exudates remain without a definitive diagnosis (3.8% in our study). However, in undiagnosed pleural effusions there remains a risk of malignancy as shown in previous publications [19]. It would be reassuring for patients and physicians to be able to quickly and effectively differentiate MPE from non-MPE with the aid of transthoracic US. In addition, this would allow the physician to avoid further investigations in low-probability

cases with small effusions and the presence of relative contraindications or to immediately adopt a high-yield diagnostic strategy in patients with a high probability of malignancy.

In clinical practice, thorax CT scans are usually performed during the investigation of undiagnosed pleural effusions [4]. They can be useful for distinguishing MPE from non-MPE. Leung et al. [20] and Qureshi et al. [11] showed that nodularity and thickening of the parietal pleura of more than 10 mm had a low sensitivity (42–56%) but a high specificity (88–95%) for malignancy.

Table 4. Diagnostic yield of US features for malignancy

US features for malignancy	Sensitivity, %	Specificity, %	PPV, %	NPV, %	Accuracy, %
Heterogeneous echogenic pattern present	80.3	56.7	64.6	74.5	68.4
Septated pattern absent	92.4	25.4	54.9	77.3	58.6
Swirling sign present	57.6	85.1	79.1	67.1	71.4
Pleural/diaphragmatic thickness >10 mm	74.2	86.6	84.4	77.3	80.4
Pleural/diaphragmatic nodularity	78.8	91.0	89.7	81.3	85.0
Lung air bronchogram sign absent	92.4	31.3	57.0	80.8	61.7
Presence of chest wall invasion	3.0	100.0	100.0	51.1	51.9
Peripheral lung lesion present	13.6	100.0	100.0	54.0	57.1
Hepatic metastasis present	6.1	100.0	100.0	51.9	53.4
Overall yield ^a	80.3	83.6	82.8	81.2	81.9

PPV = Positive predictive value; NPV = negative predictive value. ^a Calculated based on the presence of pleural/diaphragm nodules or pleural/diaphragm thickening >10 mm or adjacent solid pulmonary lesion or hepatic metastasis.

Table 5. Logistic regression analysis of US features to predict malignancy

US features	Variable	OR (95% CI)	p value
Heterogeneous echogenic pattern	Present	1.429 (0.401–5.096)	0.582
Septated pattern	Absent	1.650 (0.273–9.973)	0.585
Swirling sign	Present	1.138 (0.300–4.317)	0.849
Pleural/diaphragmatic thickness	>10 mm	5.351 (0.899–31.848)	0.065
Pleural/diaphragmatic nodularity	Present	29.019 (7.650–110.083)	<0.001
Lung air bronchogram sign	Absent	10.416 (1.650–65.752)	0.013

Chest US has several advantages over CT, such as its availability, the fact that it is a simple and easily performed exam, that it allows for dynamic scanning and frequent reevaluations if necessary, that it is a low-cost test, and that there is no radiation exposure [13]. US has a high diagnostic yield for locating and quantifying pleural effusions as well as providing real-time guidance during thoracentesis or percutaneous biopsy [7, 8, 10]. Indeed, some of the patients we excluded did not have a pleural effusion at the time they were assessed, avoiding further unnecessary invasive procedures and radiation exposure.

Our work proves that a ‘see-hit-and-run strategy’ aimed at locating the effusion and providing guidance for thoracentesis can be optimized via a systematic US examination approach. US equipment allows detailed scanning of pleural effusion echogenicity with the evaluation of adjacent pleural and parenchymal lesions.

Several studies have assessed the usefulness of thoracic US in determining the nature of a pleural effusion. Referring to the echogenicity of the effusion, previous reports have demonstrated that a septated pattern could be

observed in MPE and non-MPE infectious effusions with similar frequency [11, 14, 21]. We found that although this US pattern can appear in both MPE and non-MPE effusions it is significantly more common in the nonmalignant group, associated with infectious disorders, namely tuberculosis and pneumonia. Our results are supported by the 30-month retrospective study of Chen et al. [22] which stated that an US septated pattern was a predictor of tuberculosis in lymphocyte-rich exudative pleural effusions [22]. The higher incidence of tuberculosis in some studies (15 cases in 67 non-MPE in our study) might explain the described differences in the varying studies [11]. A possible explanation for the higher incidence of a complex septated pattern in this pathological condition may be related to the indolent course and intense pleural inflammation.

It has also been reported that US presence of nodular protrusions on the parietal or visceral pleura and other pleural abnormalities such as increased thickness and invasion of adjacent thoracic structures have a high specificity for malignancy [11, 14]. In 2009, Qureshi et

al. [11] showed that US features had an overall sensitivity of 79% and a specificity of 100% in distinguishing MPE from non-MPE. The differentiation was better than on the performed CT scan [11]. In our study pleural/diaphragmatic nodularity was the most relevant US feature to predict malignancy. Pleural metastases were of variable size and echogenicity and were found mainly in basal and dependent pleural areas. This was possibly related to the force of gravity or the greater vascularity promoting the deposition and adhesion of tumor cells. Still, we found 6 false-positive cases with pleural nodules in patients with tuberculosis, proving that nodularity is not pathognomonic of malignancy. Furthermore, some non-MPE cases were misclassified by thoracic US with pleural/diaphragmatic thickening of over 10 mm. The low overall negative predictive value emphasizes the need to confirm all suspicious cases via more invasive tests. Patients with negative cytology and US features suggestive of malignancy should undergo further invasive procedures since therapeutic decisions depend on positive tissue results.

Our results show some differences in comparison to the study of Chian et al. [23] who reported the presence of a positive US swirling pattern within an effusion as a useful predictor of MPE in patients with underlying malignancies [23]. We found that this sign was present in exudates related to the existence of circular floating debris but did not appear to be sensitive or specific for malignancy.

We have confirmed that lung air bronchogram signs are more frequently positive in lung infiltrates caused by infectious diseases. The presence of linear inlets or tree-shaped hyperechoic reflexes within a hypoechoic area was described in 97% of cases of peripheral pneumonia [24]. One of the limitations of that study was that other diseases were not included and specificity could not be assessed. Reissig et al. [25] addressed this matter in a prospective multicenter study and reported a diagnostic sensitivity and specificity of 93.4 and 97.7%, respectively, with 86.7% of cases showing air bronchograms [25]. In our study, the absence of an air bronchogram sign had a high sensitivity (92.4%) and low specificity (31.3%) for malignancy. An article published by Kuo et al. [26] using radial endobronchial US also proved that the absence of an air bronchogram was able to distinguish between benign and malignant lesions. In malignant obstructive pneumonias or infiltrates the sign may cause a false-negative diagnosis. If US characteristics do not improve on follow-up, the possibility of a malignant diagnosis needs to be considered. A fluid bronchogram sign has been de-

scribed in tumors associated with obstructive pneumonia although it was not visualized in our population [27].

The following US criteria were described to predict chest wall invasion with high sensitivity and specificity: disruption of the pleural surface reflection, extension of the tumor through the chest wall, rib invasion, and tumor fixation during breathing [28, 29]. We found such morphological findings in 2 cases. While they were not very common in our population, along with hepatic metastasis or detection of peripheral lung lesions they had a high specificity for malignancy.

Based on the present data, patients with an exudative pleural effusion, a negative cytology/needle biopsy, and normal pleural adenosine deaminase values as well as pleural nodularity and absence of an air bronchogram on US should be referred for more invasive diagnostic procedures.

Some limitations of our study need to be mentioned. It remains unclear whether thoracic US is able to improve the diagnostic algorithm or benefit patients with an MPE. We did not evaluate the clinical impact of US on the future status of our patients. This study was conducted in a single center although the images were reviewed by chest physicians from different institutions, so the present findings require further confirmation in a multicenter trial.

Another relevant point is that US is clearly operator dependent and US image discrimination requires expertise so other investigators or groups may prove more or less skillful and this may change the diagnostic yield. Nevertheless, in recent years US equipment has become increasingly accessible to pulmonologists. The introduction of other sonographic imaging techniques such as endobronchial US may contribute to improving image interpretation, shortening the learning curve, and enhancing the operators' experience. In the digital era, recording of the entire US exam might be of value for pulmonologists to request external consultancy when doubt persists. With adequate training, chest physicians may be able not only to correctly identify pleural effusions but also to perform advanced transthoracic US scanning.

Conclusions

Our prospective study showed that, in the presence of a pleural effusion of unknown etiology, transthoracic US features examined by pulmonologists can be useful to differentiate MPE from non-MPE. The presence of

pleural nodularity and absence of an air bronchogram sign seem to be the most important differentiating findings. Other US characteristics such as increased pleural thickness, absence of a septated echogenic pattern, and a positive swirling sign may be of assistance to diagnose malignancy, especially if added to clinical data. This simple and widespread technique might be important for the safe triage of patients for more invasive procedures when thoracentesis fails to provide a definitive diagnosis.

Financial Disclosure and Conflicts of Interest

All authors state that they have no potential conflict of interest related to this work.

Acknowledgements

The authors would like to thank Mercês Leonardo, Susana Carreira, and Cepeda Ribeiro for their assistance and support throughout this study.

References

- Villena V, López Encuentra A, Echave-Sustaeta J, Alvarez Martínez C, Martín Escribano P: Prospective study of 1,000 consecutive patients with pleural effusion: etiology of the effusion and characteristics of the patients. *Arch Bronconeumol* 2002;38:21–26.
- Postmus PE, Brambilla E, Chansky K, Crowley J, Goldstraw P, Patz EF, Yokomise H, International Association for the Study of Lung Cancer International Staging Committee, Cancer Research and Biostatistics, Observers to the Committee, Participating Institutions: The IASLC Lung Cancer Staging Project: proposals for revision of the M descriptors in the forthcoming (seventh) edition of the TNM classification of lung cancer. *J Thorac Oncol* 2007;2:686–693.
- Rivera MP, Mehta AC, Wahidi MM: Establishing the diagnosis of lung cancer: diagnosis and management of lung cancer, 3rd ed – American College of Chest Physicians evidence-based clinical practice guidelines. *Chest* 2013;143:e142S–e165S.
- Hooper C, Lee YC, Maskell N, BTS Pleural Guideline Group: Investigation of a unilateral pleural effusion in adults: British Thoracic Society Pleural Disease Guideline 2010. *Thorax* 2010;65(suppl 2):ii4–iii17.
- Abramowitz Y, Simanovsky N, Goldstein MS, Hiller N: Pleural effusion: characterization with CT attenuation values and CT appearance. *AJR Am J Roentgenol* 2009;192:618–623.
- Arenas-Jiménez J, Alonso-Charterina S, Sánchez-Payá J, Fernández-Latorre F, Gil-Sánchez S, Lloret-Llorens M: Evaluation of CT findings for diagnosis of pleural effusions. *Eur Radiol* 2000;10:681–690.
- Koegelenberg CF, von Groote-Bidlingmaier F, Bolliger CT: Transthoracic ultrasonography for the respiratory physician. *Respiration* 2012;84:337–350.
- Diacon AH, Schuurmans MM, Theron J, Schubert PT, Wright CA, Bolliger CT: Safety and yield of ultrasound-assisted transthoracic biopsy performed by pulmonologists. *Respiration* 2004;71:519–522.
- Koegelenberg CF, Diacon AH: Image-guided pleural biopsy. *Curr Opin Pulm Med* 2013;19:368–373.
- Botana-Rial M, Leiro-Fernández V, Represas-Represas C, González Piñeiro A, Tilve-Gómez A, Fernández-Villar A: Thoracic ultrasound-assisted selection for pleural biopsy with abrams needle. *Respir Care* 2013;58:1949–1954.
- Qureshi NR, Rahman NM, Gleeson FV: Thoracic ultrasound in the diagnosis of malignant pleural effusion. *Thorax* 2009;64:139–143.
- The Royal College of Radiologists: Ultrasound Training Recommendations for Medical and Surgical Specialties, ed 2. London, The Royal College of Radiologists, 2012.
- Bugalho A, Semedo J, Alpendre J, Cepeda Ribeiro J, Carreiro L: Ultrasound in chest disease. *Rev Port Pneumol* 2010;16:589–606.
- Yang PC, Luh KT, Chang DB, Wu HD, Yu CJ, Kuo SH: Value of sonography in determining the nature of pleural effusion: analysis of 320 cases. *AJR Am J Roentgenol* 1992;159:29–33.
- Salzer WR, Eggleston JC, Erozan YS: Efficacy of pleural needle biopsy and pleural fluid cytopathology in the diagnosis of malignant neoplasm involving the pleura. *Chest* 1975;67:536–539.
- Garcia LW, Ducatman BS, Wang HH: The value of multiple fluid specimens in the cytological diagnosis of malignancy. *Mod Pathol* 1994;7:665–668.
- Nance KV, Shermer RW, Askin FB: Diagnostic efficacy of pleural biopsy as compared with that of pleural fluid examination. *Mod Pathol* 1991;4:320–324.
- Prakash UB, Reiman HM: Comparison of needle biopsy with cytologic analysis for the evaluation of pleural effusion: analysis of 414 cases. *Mayo Clin Proc* 1985;60:158–164.
- Venekamp LN, Velkeniers B, Noppen M: Does 'idiopathic pleuritis' exist? Natural history of non-specific pleuritis diagnosed after thoracoscopy. *Respiration* 2005;72:74–78.
- Leung AN, Müller NL, Miller RR: CT in differential diagnosis of diffuse pleural disease. *AJR Am J Roentgenol* 1990;154:487–492.
- Görg C, Restrepo I, Schwerk WB: Sonography of malignant pleural effusion. *Eur Radiol* 1997;7:1195–1198.
- Chen HJ, Hsu WH, Tu CY, Yu YH, Chiu KL, Hang LW, Hsia TC, Shih CM: Sonographic septation in lymphocyte-rich exudative pleural effusions: a useful diagnostic predictor for tuberculosis. *J Ultrasound Med* 2006;25:857–863.
- Chian CF, Su WL, Soh LH, Yan HC, Perng WC, Wu CP: Echogenic swirling pattern as a predictor of malignant pleural effusions in patients with malignancies. *Chest* 2004;126:129–134.
- Reissig A, Kroegel C: Sonographic diagnosis and follow-up of pneumonia: a prospective study. *Respiration* 2007;74:537–547.
- Reissig A, Copetti R, Mathis G, Mempel C, Schuler A, Zechner P, Aliberti S, Neumann R, Kroegel C, Hoyer H: Lung ultrasound in the diagnosis and follow-up of community-acquired pneumonia: a prospective, multicenter, diagnostic accuracy study. *Chest* 2012;142:965–972.
- Kuo CH, Lin SM, Chen HC, Chou CL, Yu CT, Kuo HP: Diagnosis of peripheral lung cancer with three echoic features via endobronchial ultrasound. *Chest* 2007;132:922–929.
- Yang PC, Luh KT, Wu HD, Chang DB, Lee LN, Kuo SH, Yang SP: Lung tumors associated with obstructive pneumonitis: US studies. *Radiology* 1990;174:717–720.
- Suzuki N, Saitoh T, Kitamura S: Tumor invasion of the chest wall in lung cancer: diagnosis with US. *Radiology* 1993;187:39–42.
- Bandi V, Lunn W, Ernst A, Eberhardt R, Hoffmann H, Herth FJ: Ultrasound versus CT in detecting chest wall invasion by tumor: a prospective study. *Chest* 2008;133:881–886.