

## UPDATED CLINICAL PRACTICE GUIDELINES

**Editor's Choice – Update of the European Society for Vascular Surgery (ESVS) 2020 Clinical Practice Guidelines on the Management of Acute Limb Ischaemia in Light of the COVID-19 Pandemic, Based on a Scoping Review of the Literature**

Vincent Jongkind<sup>a,\*</sup>, Jonathan J. Earnshaw<sup>b</sup>, Frederico Bastos Gonçalves<sup>c</sup>, Frederic Cochennec<sup>d</sup>, E. Sebastian Debus<sup>e</sup>, Robert Hincliffe<sup>f</sup>, Gabor Menyhei<sup>g</sup>, Alexei V. Svetlikov<sup>h</sup>, Yamume Tshomba<sup>i</sup>, Jos C. Van Den Berg<sup>j</sup>, Martin Björck<sup>k</sup>

<sup>a</sup> Department of Vascular Surgery, Amsterdam University Medical Centres, Amsterdam, the Netherlands

<sup>b</sup> Gloucestershire Hospitals NHS Foundation Trust, UK

<sup>c</sup> NOVA Medical School, Universidade NOVA de Lisboa & Centro Hospitalar Universitário de Lisboa Central, Portugal

<sup>d</sup> Henri Mondor University Hospital, Creteil, France

<sup>e</sup> Department for Vascular Medicine (Vascular Surgery, Angiology, Endovascular Therapy), University Heart & Vascular Centre, University Hospital Hamburg-Eppendorf, Hamburg, Germany

<sup>f</sup> Bristol Centre for Surgical Research, Bristol NIHR Biomedical Research Centre, Bristol, UK

<sup>g</sup> Department of Vascular Surgery, University of Pecs, Pecs, Hungary

<sup>h</sup> Division of Cardio-Vascular of the North-Western Medical University named after II Mechnikov, St Petersburg, Russia

<sup>i</sup> Unit of Vascular Surgery, Fondazione Policlinico Universitario Gemelli IRCCS, Roma - Università Cattolica del Sacro Cuore, Rome, Italy

<sup>j</sup> Service of Interventional Radiology Centro Vascolare Ticino Ospedale Regionale di Lugano and Universitätsinstitut für Diagnostische, Interventionelle und Pädiatrische Radiologie Inselspital, Bern, Switzerland

<sup>k</sup> Department of Surgical Sciences, Uppsala University, Uppsala, Sweden

**WHAT THIS PAPER ADDS**

This is the first scoping review of the literature focusing on how the clinical practice guidelines on acute limb ischaemia (ALI) may need to be adapted as a result of the COVID-19 pandemic. It is important to optimise the care of patients suffering from both COVID-19 and ALI.

**Objective:** To perform a scoping review of how patients with COVID-19 are affected by acute limb ischaemia (ALI) and evaluate the recommendations of the 2020 ESVS ALI Guidelines for these patients.

**Methods:** Research questions were defined, and a systematic literature search was performed following the PRISMA guidelines. Abstracts and unpublished literature were not included. The definition of ALI in this review is in accordance with the ESVS guidelines.

**Results:** Most identified papers were case reports or case series, although population based data and data from randomised controlled trials were also identified. In total, 114 unique and relevant papers were retrieved. Data were conflicting concerning whether the incidence of ALI increased, or remained unchanged, during the pandemic. Case reports and series reported ALI in patients who were younger and healthier than usual, with a greater proportion affecting the upper limb. Whether or not this is coincidental remains uncertain. The proportion of men/women affected seems unchanged. Most reported cases were in hospitalised patients with severe COVID-19. Patients with ALI as their first manifestation of COVID-19 were reported. Patients with ALI have a worse outcome if they have a simultaneous COVID-19 infection. High levels of D-dimer may predict the occurrence of arterial thromboembolic events in patients with COVID-19. Heparin resistance was observed. Anticoagulation should be given to hospitalised COVID-19 patients in prophylactic dosage. Most of the treatment recommendations from the ESVS Guidelines remained relevant, but the following were modified regarding patients with COVID-19 and ALI: 1) CTA imaging before revascularisation should include the entire aorta and iliac arteries; 2) there should be a high index of suspicion, early testing for COVID-19 infection and protective measures are advised; and 3) there should be preferential use of local or locoregional anaesthesia during revascularisation.

**Conclusion:** Although the epidemiology of ALI has changed during the pandemic, the recommendations of the ESVS ALI Guidelines remain valid. The above mentioned minor modifications should be considered in patients with COVID-19 and ALI.

**Keywords:** Acute limb ischaemia, COVID-19, Peripheral arterial disease

Article history: Received 24 July 2021, Accepted 26 August 2021, Available online 6 September 2021

© 2021 The Authors. Published by Elsevier B.V. on behalf of European Society for Vascular Surgery. This is an open access article under the CC BY license (<http://creativecommons.org/licenses/by/4.0/>).

\* Corresponding author. Department of Vascular Surgery, Amsterdam UMC, location AMC, Meibergdreef 9, P.O. Box 22660, Amsterdam, 1100 DD, the Netherlands. E-mail address: [v.jongkind@amsterdamumc.nl](mailto:v.jongkind@amsterdamumc.nl) (Vincent Jongkind).

1078-5884/© 2021 The Authors. Published by Elsevier B.V. on behalf of European Society for Vascular Surgery. This is an open access article under the CC BY license (<http://creativecommons.org/licenses/by/4.0/>). <https://doi.org/10.1016/j.ejvs.2021.08.028>

## INTRODUCTION

In February 2020 the European Society for Vascular Surgery (ESVS) 2020 Clinical Practice Guidelines on the Management of Acute Limb Ischaemia (ALI) were published.<sup>1</sup> They were the first ever guidelines to be published focusing on how to treat patients with ALI, irrespective of aetiology. The publication of this document coincided with the start of the COVID-19 pandemic, and was timely, as both venous and arterial thrombosis have been recognised as important manifestations of the disease.<sup>2,3</sup> In April 2020 the editors of this journal made an early call for research initiatives linked to the pandemic.<sup>4</sup> One important question is whether the diagnostic and management recommendations issued in the ALI Guidelines are applicable to a patient who develops ALI as a manifestation of COVID-19, or if the recommendations require adjustment. It is also important to try to understand how the pandemic has affected the epidemiology of ALI. It was difficult for the writing committee (WC) to perform this analysis at the very beginning of the pandemic, as there were simply not enough data, and only personal observations and case reports were available.

Most of the members of the ALI Guidelines WC agreed to perform a scoping review to address this issue, and it was completed in July 2021. The aim of the scoping review was to determine the extent of research performed on how patients with COVID-19 infection are affected by ALI, summarise the findings, identify knowledge gaps, and evaluate whether specific recommendations of the 2020 ESVS ALI Guidelines need to be modified for the diagnosis and management of this new and large patient group.

## METHODS

A scoping review was performed according to PRISMA Protocols Extension for Scoping Reviews.<sup>5</sup> A systematic search strategy was used. A literature search of articles in the PubMed and EMBASE databases was performed up to 22 June 2021. The following search terms were used: COVID-19, corona virus, coronavirus, SARS-COV2, acute limb ischaemia. No limitations were used. Reference checking and manual searching by the members of the WC added other relevant literature. Only full text original articles published in peer reviewed journals were considered eligible. Abstracts and unpublished literature were excluded. The definition of ALI in the published guidelines<sup>1</sup> was the following: "ALI is characterised by a sudden decrease in arterial perfusion of the limb, with a potential threat to limb survival, requiring urgent evaluation and management. ALI is considered when the symptom duration is less than two weeks". In this review, ALI was considered to be associated with COVID-19 infection when the event occurred within 30 days from the onset of the COVID-19 infection, or during a hospital stay for COVID-19 infection. Also considered was any ALI occurring within 30

days of vaccination to prevent COVID-19. In clinical practice it is sometimes uncertain which event occurred first, the COVID-19 infection or the ALI, and this can be dependent on the frequency and sensitivity of testing for COVID-19. With this 30 day limit for association between the two events, however, the definition is inclusive. Any studies describing patients with ALI that could be associated with COVID-19 infection were included. Also, studies describing the effect of the COVID-19 pandemic on care for patients with ALI were included. Narrative reviews and editorials were excluded, as were studies describing only venous thrombosis or chronic limb threatening ischaemia. Screening of abstracts and selection based on full text review was performed by two authors (VJ, AS). Apart from the systematic search, manual searching by the members of the WC retrieved additional studies.

**Table 1. Pre-defined questions for a literature search of how patients with COVID-19 are affected by acute limb ischaemia (ALI)**

Section	Specific questions
Epidemiology	Are there indications that the number of patients treated for ALI has increased during the pandemic?
	Has the age and sex of the patients treated changed?
	Has the proportion of upper and lower limb ischaemia changed?
	The proportion of embolus vs. thrombosis?
	Has the number of simultaneous venous and arterial thromboses changed?
	Is the outcome of ALI in patients infected with COVID-19 different from other forms of ALI?
Pathophysiology	Is there a specific pathophysiology of ALI in patients infected with COVID-19?
	Are there results from pathology investigations in patients infected with COVID-19 with ALI?
	Are synchronous multifocal occlusions common?
Diagnosis	Is computed tomography angiography still the first choice imaging modality?
	Any new biomarkers that have been used in patients infected with COVID-19?
Initial management	Should intravenous heparin be administered as initial management?
Open surgery	Has the proportion treated by open and endovascular surgery changed?
	Are there specific reasons to primarily choose open or endovascular surgery?
Thrombolysis	Is there a need for systemic heparinisation during thrombolysis considering an increased thrombogenicity?
	Is enhancement of thrombolysis with percutaneous mechanical thrombectomy beneficial?
Other	Is intensified follow up required?
	Are there data on best anticoagulation postintervention?

Specific research questions were defined by consensus among the WC prior to the systematic search (Table 1) and divided between the authors in groups of two or three persons who read the selected manuscripts considering their specific research question. The results were then communicated within the entire group of authors. According to methodology for scoping reviews, a descriptive narrative of the data is presented and no data analysis is performed.<sup>6</sup>

## RESULTS

The search strategy identified 226 studies. Some 53 studies were excluded based on title and abstract. After reading full texts, 114 studies were included in the review (Fig. 1). There were 89 case reports or small series ( $n < 10$ ), one randomised controlled trial (RCT), three systematic reviews, and nine cohort studies reporting on 13 – 49 patients with ALI associated with COVID-19. Other included studies included cohort studies only on incidence or mortality of ALI associated with COVID-19, or review of organisation of care for ALI during the pandemic. A complete reference list of all included studies is presented in Appendix A. No studies were identified reporting ALI in patients after receiving vaccination to prevent COVID-19.

### Pathophysiology

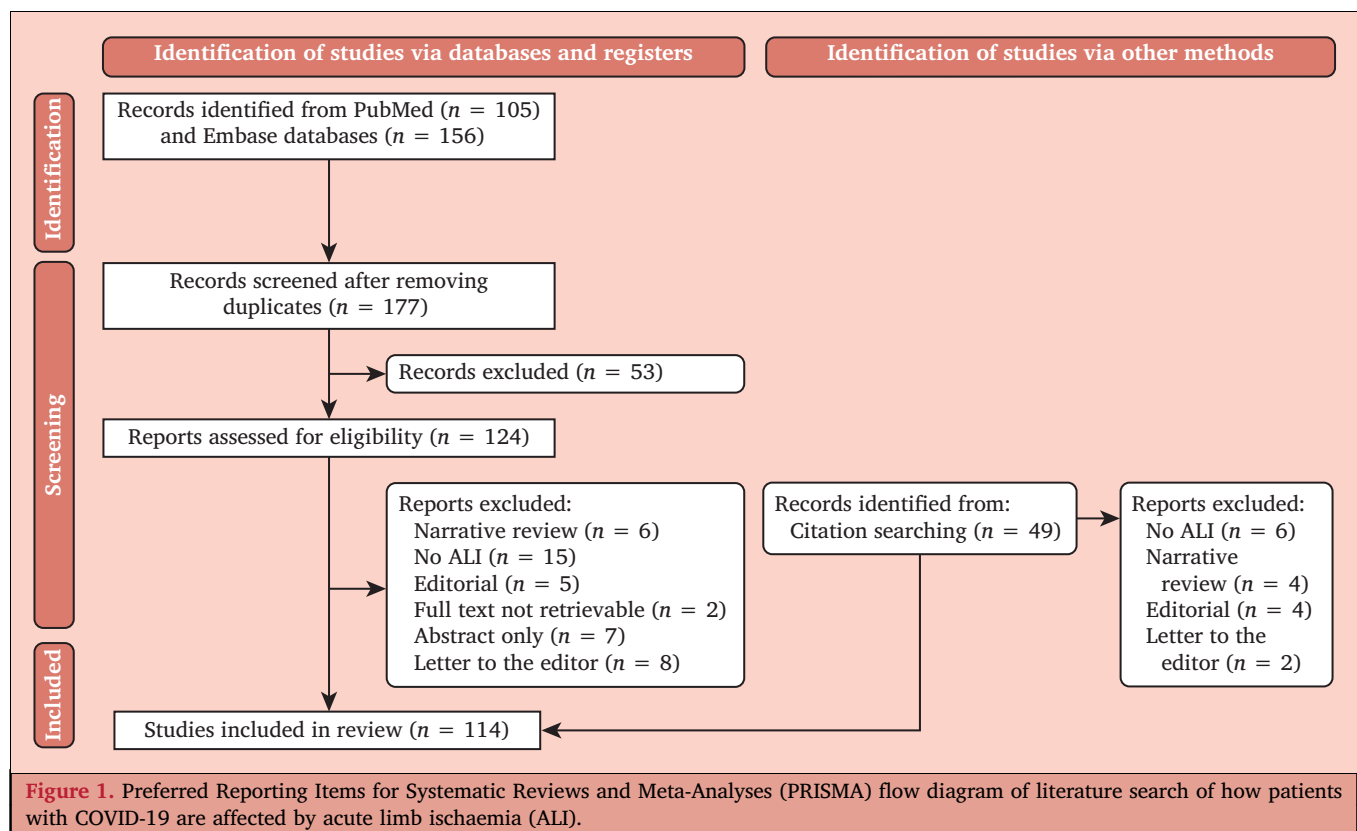
In patients with pre-existing peripheral arterial disease (PAD), it may be difficult to ascertain whether the cause of ALI was related to a “normal” atherosclerotic process, or if

it was influenced or precipitated by the presence of COVID-19. The pathophysiology of COVID-19 associated ALI is multifactorial and not yet fully understood. Coagulopathy, hyperinflammation, and endothelial injury play a role, leading to micro- and macrovascular thrombosis.<sup>7–9</sup> Endothelial injury and infiltration by inflammatory cells can occur in previously healthy endothelium. In pathology specimens after major amputation following COVID-19 associated ALI in patients without a history of peripheral arterial disease, inflammation of the endothelium with small vessel congestion was found.<sup>10</sup> There are multiple case reports of COVID-19 associated ALI in patients without known peripheral arterial disease, and even in young patients without comorbidities or atherosclerosis.<sup>11–15</sup>

Coagulopathy is most apparent in hospitalised patients with severe COVID-19 infection, but COVID-19 associated ALI is also reported in patients with mild COVID-19 symptoms recovering at home.<sup>14–17</sup> Patients may present with ALI as their first manifestation of COVID-19 infection.<sup>15,18,19</sup> Two case reports reported that ALI may occur in patients with mild symptoms of COVID-19, and in individuals who are otherwise asymptomatic or have no respiratory symptoms.<sup>20,21</sup>

### Epidemiology

The first research questions focused on how the epidemiology of ALI may have changed during the pandemic. The data on the number of patients being treated with ALI during the COVID-19 pandemic are heterogeneous and conflicting. This is hardly surprising given that the number



of patients with ALI presenting to vascular surgeons is likely to be influenced by the phase of the pandemic, local COVID-19 prevalence rates, public health and specialty guidelines in surgery and vascular surgery, as well as the availability of local resources.

Data from the US and Italy suggested that the pandemic had a major impact on the delivery of vascular services in general.<sup>22–24</sup> In Italy when resources were particularly stretched during the first wave, ALI was the most frequent presentation of peripheral vascular disease requiring surgical treatment.<sup>24</sup> In contrast, the proportions of patients receiving operations for acute and chronic limb ischaemia in Sweden were unchanged in 2020 compared with the period 2017 – 2019.<sup>26</sup> The numbers of patients admitted to hospital in Germany with acute limb ischaemia declined by 12% from the pre-COVID-19 period (January – May 2019) to January – May 2020 (5.1 – 4.6 per 100 000 insured patients).<sup>27</sup>

Potential concerns were raised early in the pandemic among vascular surgeons that a reduction in elective surgical capacity and treatment, combined with delayed presentations may increase the rates and severity of ALI. However, data from Portugal suggest that there was no evidence that patients presented later with more advanced ALI during the early part of the pandemic.<sup>28</sup>

The incidence of ALI in patients who are admitted to hospital with mild symptoms from COVID-19 is relatively low: 0.4% – 0.9%.<sup>19,29–32</sup> In critically ill patients who need intensive care it is higher. In a systematic review of five cohort studies, the prevalence of ALI was 2.5% (58% of all arterial thromboses) in patients critically ill with COVID-19.<sup>7</sup> Similar incidences of ALI in critically ill patients who were treated with prophylactic or therapeutic anticoagulation were found by (multicentre) studies from France and Italy: 0.6%,<sup>33</sup> 2.2%,<sup>34</sup> and 2.4%.<sup>16</sup>

Another important question is whether there has been a change in demographics of ALI as a result of COVID-19, namely age, sex, and ethnic background. Most of the patients presenting with ALI and COVID-19 were men, elderly (aged > 60 years), and had co-morbidities.<sup>7</sup> Similar sex distributions were identified in Turkey<sup>30</sup> (16.7% women) and Peru<sup>18</sup> (23.3% women), with most patients being men, elderly, and with significant comorbidities. Nevertheless, there are several reports of ALI in patients suffering from COVID-19 who have no known peripheral arterial disease, and even in young patients without comorbidities or significant pre-existing atherosclerosis.<sup>4,11–15,30</sup> Although these reports do exist, suggesting the existence of a new group with ALI, there are no large population based studies that can verify this observation.

Some studies highlighted that a significant proportion (12% – 18%) of patients have evidence of thrombus in multiple arterial locations including the aorta, visceral arteries, cerebral arteries, coronary arteries, but that most are located in the lower limb.<sup>7,11,12,17,19</sup> The present review did

not find data on the proportion of embolus vs. thrombosis in patients with ALI.

Although the focus of this review was arterial thrombosis and embolism leading to ALI, an increased tendency of simultaneous venous and arterial thrombosis could affect the outcome of ALI. Some patients with COVID-19 develop a generalised pro-thrombotic state and may suffer concomitant arterial and venous thrombosis. In one study, 16% of patients with ALI were found to have a concomitant deep vein thrombosis.<sup>19</sup>

### **Diagnosis and imaging**

The 2020 ALI guidelines recommended preferential use of computed tomography angiography (CTA) when imaging patients with ALI, because of its availability and usefulness for planning treatment.<sup>1</sup> Although the recommendations did not specifically mention that CTA should include the entire vascular tree (from the supra-aortic trunks to the feet), in most centres complete imaging is actually performed. In patients with COVID-19 presenting with lower limb ALI, however, there is often anatomically more extensive disease, and a greater clot burden, with concomitantly higher rates of amputation.<sup>34</sup> For this reason, it is recommended that complete imaging with CTA from aortic arch to the feet/hands should be used in these patients. The latter also allows exclusion of other thromboembolic events such as pulmonary thromboembolism, cardiac thrombi, and aortic thrombus that have been reported to occur relatively often in combination with lower limb ALI in patients with COVID-19.<sup>7</sup>

### **Laboratory tests**

Global haemostatic tests (e.g., thrombo-elastography and clot wave analysis) may be useful in early identification of hypercoagulable states leading to thromboembolic events.<sup>35–38</sup> Laboratory coagulation monitoring (D-dimer, prothrombin time, fibrinogen and platelet count) might identify patients at increased thrombotic risk, and/or who are in a hypercoagulable state or even disseminated intravascular coagulation.<sup>39</sup> A high level of D-dimer (the exact levels depend on the laboratory method used) might have predictive value for the occurrence of arterial thromboembolic events in patients with COVID-19.<sup>40,41</sup>

### **Prophylactic anticoagulation**

Patients with COVID-19 may have abnormal coagulation patterns interfering with adequate therapeutic anticoagulation; ALI may even occur in critically ill patients suffering from COVID-19, despite receiving anticoagulation at prophylactic or therapeutic dosages.<sup>16,33,34</sup> Multiple studies are currently being performed to identify the best prophylactic anticoagulation strategy for (subgroups of) patients with COVID-19. In one randomised controlled trial (RCT) from Brazil, 615 patients with COVID-19 and elevated

D-dimer levels were studied to evaluate the potential benefit of therapeutic (vs. prophylactic) anticoagulation in this subgroup of patients considered to be at higher risk of thrombotic events.<sup>32</sup> No difference was found in the composite thrombotic outcome (7% vs. 10%,  $p = .32$ ), but bleeding complications increased (8% vs. 2%,  $p = .001$ ). There was only one patient who developed ALI in the study. Another multicentre RCT from Iran on 600 patients found no benefit of intermediate dose vs. standard dose prophylactic anticoagulation among patients with COVID-19 admitted to the intensive care unit (ICU).<sup>42</sup> A systematic review with meta-analysis on cohort studies was published showing benefit for prophylactic anticoagulation over no anticoagulation.<sup>43</sup> Anticoagulation at therapeutic dose might benefit some subgroups, but also increases the risk of bleeding.

### Initial management and referral

Initial management of patients with ALI during the COVID-19 pandemic is similar, and the recommendations in the guidelines (9–14) are still valid: adequate analgesia, intravenous rehydration, supplementary oxygen, and intravenous heparin.<sup>1</sup> As discussed under *Diagnosis*, some patients present with ALI as their first symptom of COVID-19 infection. Thus, a high index of suspicion, early testing for COVID-19 infection, and protective measures are advised for all patients presenting with ALI during the pandemic.

Timely review by a vascular specialist remains critical in the management of patients with COVID-19 and ALI.<sup>44</sup> Therapeutic anticoagulation with intravenous unfractionated heparin (bolus followed by continuous infusion) should be provided once a diagnosis of ALI is established, unless there are significant contraindications such as active or serious bleeding in the previous 24–48 hours, or recent surgery. This is similar to Recommendation #9 in the ALI Guidelines, but the importance of early heparinisation is underlined during the pandemic. In addition, patients with COVID-19 may have abnormal coagulation patterns interfering with adequate therapeutic anticoagulation: heparin resistance, which is rare overall, has been observed among COVID-19 patients, although the exact incidence is uncertain.<sup>41</sup> Early and frequent assessment of APTT, activated clotting time or factor anti Xa levels can be of value. Currently, there are no data suggesting superiority of any form of anticoagulation: unfractionated heparin, low molecular weight heparin, or direct oral anticoagulants.<sup>43</sup>

### Decision making

Based on a patient's overall clinical presentation, a decision is needed on whether an intervention is beneficial and what kind of intervention is appropriate. It is crucial to consider the severity of systemic illness when considering intervention, particularly when considering open arterial surgery. Because of the severe pulmonary complications associated

with COVID-19, critically ill patients may not be candidates for any kind of surgical revascularisation; “*life before limb*” will be justified in these situations.

There are no high quality data to inform the choice for open vs. endovascular intervention for COVID-19 associated ALI. Both have been associated with successful limb salvage, and both have also been associated with high mortality and morbidity rates. The choice is probably influenced by specific anatomical considerations (e.g., presence of atherosclerotic plaque, aneurysm), operator preference, and institutional resources. These observations underline the importance of Recommendation #13 of the ESVS Guidelines:<sup>1</sup> that patients diagnosed with ALI are treated in a vascular centre that offers the full range of open and endovascular interventions.

### Open surgical treatment

Open surgical treatment using thromboembolectomy remains the most common revascularisation technique in many countries and centres. The present review found no data implying that there is a need to modify the recommendations (15–21) in the Guidelines covering open surgical treatment.<sup>1</sup>

Because of hypercoagulation status, the risk of minor amputation following surgical thrombectomy may be higher than normal, a result of distal microvessel thrombosis.<sup>11</sup> Intra-arterial locoregional thrombolysis using alteplase may be considered as an adjunct to thromboembolectomy, especially in patients with residual distal thrombus, and foot ischaemia. In one study of 15 patients, this approach was used in four of five patients with distal occlusions.<sup>44</sup> No bleeding complications occurred, and limb salvage was achieved in 14 patients of the entire cohort of 15 patients (93.3%). Likewise, improved long term results when using intra-operative intra-arterial thrombolysis in patients with ALI and popliteal artery aneurysms (who were not COVID-19+) were recently reported in a comparative study using propensity score matching (major adverse limb events 30% vs. 65%,  $p < .001$ ).<sup>45</sup>

To avoid any airway manipulation, regional anaesthesia might be preferable over general anaesthesia. Benefits of regional anaesthesia include preservation of respiratory function, and avoidance of aerosolisation and hence less viral transmission to staff members.<sup>46</sup> This may be especially important in patients with COVID-19. There is no scientific evidence to support this theory, although one cohort series showed that local anaesthesia with sedation or locoregional anaesthesia was feasible for thromboembolectomy or bypass in 17 patients.<sup>44</sup> Recommendation #15 in the ESVS Guidelines states: “For patients requiring surgical thromboembolectomy for acute limb ischaemia, regional or local anaesthesia may be considered, but always with an anaesthetist present (Class IIb, Level C)”.<sup>1</sup> The authors of this paper agree that this recommendation needs to be strengthened during the pandemic, and recommend

the preferential use of local or locoregional anaesthesia for open surgery of ALI in patients with COVID-19.

### Endovascular treatment

Thirteen patients were identified, from eight publications, with catheter directed thrombolysis (CDT) in COVID-19 associated ALI (for details, see Table 2).<sup>47–54</sup> Percutaneous mechanical thrombectomy (PMT) was used (simultaneously) in some patients. During CDT, continuous heparinisation was performed in at least four cases.<sup>48–50,53</sup> Two reports described the successful use of thrombolysis or PMT for re-occlusion after open surgical thrombo-embolectomy.<sup>52,54</sup>

Since the publication of the 2020 ESVS ALI guidelines, one important paper has been published describing good outcomes using PMT in (non-COVID) patients with ALI, confirming the potential role of percutaneous thrombectomy techniques in the management of ALI.<sup>55</sup> Given the limited resources in ICUs and high dependency units during the pandemic, any technique reducing the time spent in critical care constitutes an obvious advantage. These observations underline the importance of Recommendation #33 in the ESVS Guidelines,<sup>1</sup> stating: “For patients with acute limb ischaemia, aspiration and mechanical thrombectomy should be considered (Grade IIa, Level C)”.

One issue that was studied with particular interest was whether Recommendation #29 against using continuous systemic therapeutic heparinisation during thrombolysis would need to be modified.<sup>1</sup> No data were identified from the literature suggesting this. The specific risks and benefits of systemic therapeutic heparinisation may be different from those in non-infected patients, but no data were identified to support modification of the treatment algorithms.

### Outcomes after treatment

Emerging patterns suggest that the outcomes of patients with ALI are worse in patients with COVID-19 (Table 3). Imaging studies in a North American cohort found that the mortality

**Table 3. Mortality reported by seven series on >15 patients infected with COVID-19 and presenting with and / or receiving intervention for acute limb ischaemia**

Author	Country	Patients – n	Mortality – %
Behrendt <sup>57</sup>	Germany	63	14.1
Bellosta <sup>44</sup>	USA	20	40
Benson <sup>56</sup>	19 countries	93	20.4
Etkin <sup>19</sup>	USA	35	50
Goldman <sup>34</sup>	USA	16	37.5
Kahlberg <sup>25</sup>	Italy	41	29.3
Sanchez <sup>18</sup>	Peru	30	23

and amputation rates of patients with ALI were much worse with simultaneous COVID-19 compared with a propensity score matched historical control group.<sup>34</sup> Adjusted for history of peripheral arterial disease, death or limb amputation was more common in patients with COVID-19 (odds ratio 25; 95% CI 4.3 – 147;  $p < .001$ ). A non-population based international multicentre study of outcomes after 1 103 open and endovascular interventions for ALI in patients with COVID-19 from 57 centres in 19 countries found mortality of 20.4% in 93 patients with COVID-19.<sup>56</sup>

The reasons for worse outcomes may be related to a reluctance amongst surgeons to operate on ALI in severely ill patients with COVID-19 infection (perceived futility), late presentation with severe ischaemia (there is surprisingly little evidence for this – see above), and worse outcomes following the revascularisation itself. In a series from New York, revascularisation was performed in only 27% of patients and primary amputation in 10%.<sup>19</sup> The majority of patients ( $n = 28$ , 57%) were treated with systemic anticoagulation, only three (7%) with systemic tissue plasminogen activator. In Lombardy, Italy, surgeons highlighted the generally poor outcomes associated with ALI interventions. In 20 patients with lower limb ALI, revascularisation was attempted in 17 (85%), but successful in only 12 (71%) patients.<sup>44</sup> In an Italian prospective study of 305 patients referred to four vascular

**Table 2. Thrombolysis in 13 patients with acute limb ischaemia and COVID-19 as reported in eight studies**

Author	n	COVID-19 severity	Rutherford stage	Technique	Technical success	Limb salvage and/or survival
Aasen <sup>47</sup>	5	Mild	IIa	CDT+PMT	Yes	Yes
		Mild	IIa	CDT+PMT	Yes	Yes
		Severe	IIa	CDT+PMT	No	Deceased
		Severe	IIa	CDT+PMT	No	Deceased
Maurera <sup>48</sup>	1	Mild	IIa	CDT + PMT	Yes	Yes
		Mild	IIa	CDT+PMT	Yes	Transmetatarsal amputation
		Mild	IIa	CDT + PMT	Yes	Yes
		Mild	IIa	CDT	Yes	Yes
Vacirca <sup>50</sup>	1	Severe	IIa	CDT	No <sup>†</sup>	Yes
Horani <sup>51</sup>	1	Severe	IIa	CDT+PMT	No	Deceased
Pasqui <sup>52</sup>	2	Mild	IIb	CDT	No	No
		Mild	IIb	PMT*	Yes	Minor amputation
Singh <sup>53</sup>	1	Mild	IIa	CDT	Yes	Yes
Erkul <sup>54</sup>	1	Mild	IIa	CDT*	Yes	Yes

CDT = catheter directed thrombolysis; PMT = percutaneous mechanical thrombectomy.

\* For re-occlusion after open thromboembolectomy.

† Limb salvage after tibial thromboembolectomy.

surgery units during the first wave (March – April 2020), 64 (21%) patients tested positive for COVID-19. In patients with ALI, the mortality was statistically significantly higher in the COVID-19 infected group (29.3% vs. 8.9%,  $p = .014$ ).<sup>25</sup> In Germany, confirmed SARS-CoV-2 infection was associated with increased mortality in patients with ALI. When comparing ALI in patients with COVID-19 (2.4%) with those who were not infected, a higher in hospital mortality was observed (14.3% vs. 5.0%,  $p < .001$ ).<sup>57</sup>

### Acute upper limb ischaemia

Most patients presented with lower limb ALI, both before and during the pandemic. In one multicentre study from Peru, 73.3% of patients presenting with ALI had lower limb ischaemia and 26.6% had upper limb ischaemia, which is a higher proportion than expected.<sup>18</sup> Other series reported incidences of 5%,<sup>44</sup> 16.6%,<sup>19</sup> 20%,<sup>58</sup> and 25%<sup>11,59</sup> of patients with COVID-19 with ALI. In a mixed series of 97 COVID-19 positive and negative patients, the proportion of upper limb ischaemia was 10.3%.<sup>25</sup> Indes *et al.* reported a higher upper extremity involvement in COVID-19 positive patients when compared with COVID-19 negative or not tested patients (20.0% vs. 8.0%).<sup>58</sup>

The literature regarding patients with COVID-19 and upper limb ischaemia consists only of case reports or series, with a total of 43 reported patients.<sup>11,13,14,18,19,25,44,54,58–66</sup> Unfortunately, from the larger series no specific treatment details or outcomes could be retrieved. Most patients were treated by surgical thromboembolectomy, a few with thrombolysis, and for mild ischaemia (often with distal occlusion of the radial and or ulnar artery) conservative treatment with anticoagulation was performed. In several papers, in some patients revascularisation was unsuccessful, despite receiving therapeutic dose anticoagulation and undergoing arterial thromboembolectomy.<sup>14,18,54,59</sup> Reported mortality was 25% (six of 24 patients) and major amputation was required in four surviving patients (22%).<sup>11,13,14,18,44,54,59–66</sup>

### Post-operative medication and follow up

Very few data were identified regarding post-operative medication following revascularisation of ALI in patients with COVID-19. In addition, these are observational studies with small patient numbers, little detail is given on the type or dose of anticoagulation, and results seem to be contradictory.

In a study from Spain of patients who had surgery for ALI, re-thrombosis occurred in four of six patients, despite prophylactic or therapeutic anticoagulation.<sup>67</sup> In another study, 11 patients with ALI received anticoagulation therapy initiated before open or endovascular intervention. The in hospital primary patency rate was 100% and there were no major amputations in this study.<sup>59</sup> Bellosta *et al.* evaluated the data from 20 COVID-19+ patients with ALI.<sup>44</sup> Revascularisation was successful in 12 of 17 patients treated surgically. Although successful revascularisation was not significantly associated with the post-operative use of intravenous heparin in this small study, no

patient who had received intravenous heparin required re-intervention. Eight of the 20 patients died in hospital. The use of a continuous post-operative systemic heparin infusion was significantly associated with survival (mortality: 0% vs. 57.1%;  $p = .042$ ). In an Italian study, 15 patients with ALI received post-operative systemic anticoagulation with intravenous heparin.<sup>68</sup> Re-thrombosis and amputation occurred in two.

These publications suggest that the use of prolonged systemic heparin in patients with COVID-19 might improve surgical treatment efficacy and overall survival. Whether or not the long term outcome can be improved by specific anticoagulation or antiplatelet therapy remains to be seen. In the meantime, it is of great importance to follow Recommendations #44–48 of the ALI Guidelines.<sup>1</sup> Considering the high percentage of re-thrombosis, it seems particularly important to perform close and frequent follow up with physical examination of the patient, and to consider early re-intervention in case of re-occlusion.

## DISCUSSION

This is the first attempt to systematically review the literature on ALI associated with COVID-19 infection. This review aimed to determine to what extent the current ESVS recommendations for the management of ALI remain valid, or need adaptation for this special population.<sup>1</sup> Some changes were identified in the epidemiology of ALI during the pandemic, affecting younger individuals with fewer comorbidities, yet suffering worse outcomes compared with patients without COVID-19.<sup>11–15</sup> Elevated D-dimer levels increase the risk of ALI, and heparin resistance is more often observed.<sup>39–41</sup> Finally, there was no strong support to change any type of intervention for ALI, other than organisational aspects minimising the need for ICU support. Such changes include using local or locoregional anaesthesia, and endovascular techniques to effect thrombus clearance.<sup>55</sup>

This review provided no evidence that initial management, including therapeutic heparinisation, hydration, and supplementary oxygen, should be changed. These may, however, need to be adjusted to the severity of any pulmonary injury.

Although a higher dose heparin thromboprophylaxis would seem appropriate in patients with severe COVID-19,

**Table 4. Topics for future research on COVID-19 and acute limb ischaemia (ALI)**

The optimal anticoagulation prophylaxis for patients with COVID-19.
The ideal therapeutic anticoagulation strategy and monitoring in patients with COVID-19 and ALI.
The optimal management strategy for revascularisation, especially regarding factors associated with poor outcome and choice between open and endovascular revascularisation.
The potential added value or preferential use of percutaneous mechanical thrombectomy vs. standard catheter directed thrombolysis.
The risk of developing ALI during extracorporeal membrane oxygenation (ECMO) treatment, and preventive strategies

it must be balanced against the individual risk of bleeding; the results of a large RCT suggest that there is no benefit, only harm from routine anticoagulation.<sup>31</sup> For patients suffering ALI during the pandemic, treatment should not be delayed, but isolation measures should be applied until COVID infection is verified or excluded. For patients with combined COVID-19 and ALI, extended CTA is advised for investigation, given the risk of venous and arterial thrombosis in multiple locations.

One observation requiring consideration is the low rate of revascularisation attempts in severely ill patients, and as a consequence, their high mortality. The relatively good outcomes observed after revascularisation, despite a higher risk of re-thrombosis, should be taken into account when discussing intervention in these patients. After relevant modifications to the treatment algorithm, there seems to be no rationale behind denying intervention for patients with COVID-19 suffering from ALI. Therapeutic anticoagulation should be initiated as soon as possible and revascularisation should be performed promptly for patients in whom the viability of the limb is threatened (Rutherford grade IIa or IIb).

The results of this scoping review must be interpreted with caution, as the large majority of data are observational and derived from case reports or small case series, which are inherently biased. It is, however, the best evidence available to date. It is suggested that healthcare providers dealing with patients with COVID-19 should make efforts to collaborate in data collection and sharing, to improve future management.<sup>4</sup>

The following aspects were identified as important topics for future research: 1) the optimal anticoagulation prophylaxis for patients with COVID-19, including dose adaptation to the severity of the disease and optimal duration; 2) the ideal therapeutic anticoagulation strategy and monitoring in patients with COVID-19 and ALI, given the known predisposition for re-thrombosis and heparin resistance; 3) the optimal management strategy for revascularisation, especially regarding factors associated with poor outcome and choice between open and endovascular revascularisation; and 4) the potential added value or preferential use of percutaneous mechanical thrombectomy vs. standard catheter directed thrombolysis. One issue not covered by this scoping review is whether patients with COVID-19 treated with ECMO (ExtraCorporeal Membrane Oxygenation) develop ALI more often than other ECMO patients, and whether preventive strategies could reduce any risk. This is another issue to be covered by future research efforts (See Table 4).

In conclusion, this scoping review showed that the epidemiology of ALI has changed, but only slightly. The recommendations of the ESVS ALI Guidelines remain valid in the light of the COVID-19 pandemic, although some minor modifications are suggested. The Guidelines represent an important aid to clinical practice during the pandemic.

## CONFLICT OF INTEREST

None.

## FUNDING

None.

## APPENDIX A. SUPPLEMENTARY DATA

Supplementary data to this article can be found online at <https://doi.org/10.1016/j.ejvs.2021.08.028>.

## REFERENCES

- Björck M, Earnshaw JJ, Acosta S, Bastos Gonçalves F, Cochenne F, Debus ES, et al. European Society for Vascular Surgery (ESVS) 2020 Clinical Practice Guidelines on the Management of Acute Limb Ischaemia. *Eur J Vasc Endovasc Surg* 2020;**59**:173–218.
- Bilaloglu S, Aphinyanaphongs Y, Jones S, Iturrate E, Hochman J, Berger JS. Thrombosis in hospitalized patients with COVID-19 in a New York City health system. *JAMA* 2020;**324**:799–801.
- Klok FA, Kruip M, van der Meer NJM, Arbous MS, Gommers D, Kant KM, et al. Incidence of thrombotic complications in critically ill ICU patients with COVID-19. *Thromb Res* 2020;**191**:145–7.
- Björck M, Boyle JR, Dick F. The need of research initiatives amidst and after the COVID-19 pandemic: a message from the editors of the European Journal of Vascular and Endovascular Surgery. *Eur J Vasc Endovasc Surg* 2020;**59**:695–6.
- Tricco AC, Lillie E, Zarin W, O'Brien KK, Colquhoun H, Levac D, et al. PRISMA Extension for Scoping Reviews (PRISMA-ScR): Checklist and Explanation. *Ann Intern Med* 2018;**169**:467–73.
- Arksey H, O'Malley L. Scoping studies: towards a methodological framework. *Int J Soc Res Methodol Theory Pract* 2005;**8**:19–32.
- Cheruiyot I, Kipkorir V, Ngure B, Misiani M, Munguti J, Ogeng'o J. Arterial thrombosis in coronavirus disease 2019 patients: a rapid systematic review. *Ann Vasc Surg* 2021;**70**:273–81.
- Leentjens J, van Haaps TF, Wessels PF, Schutgens RE, Middeldorp S. COVID-19-associated coagulopathy and antithrombotic agents—lessons after 1 year. *Lancet Haematol* 2021;**8**:e524–33.
- Iba T, Warkentin TE, Thachil J, Levi M, Levy JH. Proposal of the definition for COVID-19-associated coagulopathy. *J Clin Med* 2021;**10**:191.
- Ilonzo N, Kumar S, Borazan N, Hansen T, Rao A, Lantis J, et al. Endotheliitis in coronavirus disease 2019-positive patients after extremity amputation for acute thrombotic events. *Ann Vasc Surg* 2021;**72**:209–15.
- Mestres G, Puigmacià R, Blanco C, Yugueros X, Esturrica M, Rimbau V. Risk of peripheral arterial thrombosis in COVID-19. *J Vasc Surg* 2020;**72**:756–7.
- Narvaneni S, Fasulo SM, Kumar V, Singh B, Sultana Y. COVID-19 induced bilateral lower limb ischemia and visceral infarcts. *Cureus* 2021;**13**:e12784.
- Perini P, Nabulsi B, Massoni CB, Azzarone M, Freyrie A. Acute limb ischaemia in two young, non-atherosclerotic patients with COVID-19. *Lancet* 2020;**395**:1546.
- Ramachandran R, Vasudevan Pillai A, Raja S, Sailesh S. Axillary artery thrombosis resulting in upper limb amputation as a COVID-19 sequela. *BMJ Case Rep* 2021;**14**:240981.
- Wengerter SP, Wengerter KR, Masoudpoor H, Sagarwala A, Karim O, Rao N, et al. Acute aortoiliac and infrainguinal arterial thrombotic events in four patients diagnosed with the novel coronavirus 2019. *J Vasc Surg Cases Innov Tech* 2020;**6**:698–702.
- de Roquetaillade C, Chousterman BG, Tomasoni D, Zeitouni M, Houdart E, Guedon A, et al. Unusual arterial thrombotic events in Covid-19 patients. *Int J Cardiol* 2021;**323**:281–4.



- 17 Veerasuri S, Kulkarni SR, Wilson WR, Paravastu SCV. Bilateral acute lower limb ischemia secondary to COVID-19. *Vasc Endovascular Surg* 2021;**55**:196–9.
- 18 Sanchez JB, Alcalde JDC, Isidro RR, Luna CZ, Cubas WS, Charres AC, et al. Acute limb ischemia in a Peruvian cohort infected by COVID-19. *Ann Vasc Surg* 2021;**72**:196–204.
- 19 Etkin Y, Conway AM, Silpe J, Qato K, Carroccio A, Manvar-Singh P, et al. Acute arterial thromboembolism in patients with COVID-19 in the New York City area. *Ann Vasc Surg* 2021;**70**:290–4.
- 20 Hanif M, Ali MJ, Haider MA, Naz S, Ahmad Z. Acute upper limb ischemia due to arterial thrombosis in a mild COVID-19 patient: a case report. *Cureus* 2020;**12**:e10349.
- 21 Thompson O, Pierce D, Whang D, O'Malley M, Geise B, Malhotra U. Acute limb ischemia as sole initial manifestation of SARS-CoV-2 infection. *J Vasc Surg Cases Innov Tech* 2020;**6**:511–3.
- 22 Mouawad NJ, Woo K, Malgor RD, Wohlauser MV, Johnson AP, Cuff RF, et al. The impact of the COVID-19 pandemic on vascular surgery practice in the United States. *J Vasc Surg* 2021;**73**:772–9.
- 23 Bath J, Aziz F, Smeds MR. Progression of changes in vascular surgery practices during the novel corona virus SARS-CoV-2 pandemic. *Ann Vasc Surg* 2021. doi: 10.1016/j.avsg.2021.03.002 [Epub ahead of print].
- 24 Boschetti GA, Di Gregorio S, Mena Vera JM, Pane B, Spinella G, Palombo D, et al. COVID 19 impact on vascular surgery practice: experience from an Italian university regional hub center for vascular pathology. *Ann Vasc Surg* 2021. doi: 10.1016/j.avsg.2021.01.072 [Epub ahead of print].
- 25 Kahlberg A, Mascia D, Bellosta R, Attisani L, Pegorer M, Socrate AM, et al. Vascular surgery during COVID-19 emergency in hub hospitals of Lombardy: experience on 305 patients. *Eur J Vasc Endovasc Surg* 2021;**61**:306–15.
- 26 Björse K, Blomgren L, Holsti M, Jonsson M, Smidfelt K, Mani K. Editor's Choice – The impact of Covid-19 on vascular procedures in Sweden 2020. *Eur J Vasc Endovasc Surg* 2021;**62**:136–7.
- 27 Seiffert M, Brunner FJ, Rimmel M, Thomalla G, Marschall U, L'Hoest H, et al. Temporal trends in the presentation of cardiovascular and cerebrovascular emergencies during the COVID-19 pandemic in Germany: an analysis of health insurance claims. *Clin Res Cardiol* 2020;**109**:1540–8.
- 28 Correia M, Constâncio V, Silva JC, Lima P, Moreira M, Antunes LF, et al. Is there an impact of COVID-19 on admission of patients to the emergency department for vascular surgery? *Ann Vasc Surg* 2020;**69**:100–4.
- 29 Topcu AC, Ozturk-Altunyurt G, Akman D, Batirel A, Demirhan R. Acute limb ischaemia in hospitalized COVID-19 patients. *Ann Vasc Surg* 2021. doi: 10.1016/j.avsg.2021.03.003 [Epub ahead of print].
- 30 Al-Zoubi N, Shatnawi N, Jarbo H. Acute lower limb ischemia in patients infected with COVID-19. *Int J Gen Med* 2021;**14**:833–9.
- 31 Lopes RD, de Barros E Silva PGM, Furtado RHM, Macedo AVS, Bronhara B, et al. Therapeutic versus prophylactic anticoagulation for patients admitted to hospital with COVID-19 and elevated D-dimer concentration (ACTION): an open-label, multicentre, randomised, controlled trial. *Lancet* 2021;**397**:2253–63.
- 32 Helms J, Tacquard C, Severac F, Leonard-Lorant I, Ohana M, Delabranche X, et al. High risk of thrombosis in patients with severe SARS-CoV-2 infection: a multicenter prospective cohort study. *Intensive Care Med* 2020;**46**:1089–98.
- 33 Fraissé M, Logre E, Pajot O, Mentec H, Plantefève G, Contou D. Thrombotic and hemorrhagic events in critically ill COVID-19 patients: a French monocenter retrospective study. *Crit Care* 2020;**24**:275.
- 34 Goldman IA, Ye K, Scheinfeld MH. Lower-extremity arterial thrombosis associated with COVID-19 is characterized by greater thrombus burden and increased rate of amputation and death. *Radiology* 2020;**297**:E263–9.
- 35 Ruberto MF, Marongiu F, Mandas A, Mameli A, Porru M, Gianchetti E, et al. The venous thromboembolic risk and the clot wave analysis: a useful relationship? *Clin Chem Lab Med* 2018;**56**:448–53.
- 36 Avila J, Long B, Holladay D, Gottlieb M. Thrombotic complications of COVID-19. *Am J Emerg Med* 2021;**39**:213–8.
- 37 Fan BE, Chia YW, Sum SLL, Kuperan P, Chan SSW, Ling LM, et al. Global haemostatic tests in rapid diagnosis and management of COVID-19 associated coagulopathy in acute limb ischaemia. *J Thromb Thrombolysis* 2020;**50**:292–7.
- 38 Bikkeli B, Madhavan MV, Jimenez D, Chuich T, Dreyfus I, Driggin E, et al. COVID-19 and thrombotic or thromboembolic disease: implications for prevention, antithrombotic therapy, and follow-up: JACC State-of-the-Art Review. *J Am Coll Cardiol* 2020;**75**:2950.
- 39 Baram A, Kakamad FH, Abdullah HM, Mohammed-Saeed DH, Hussein DA, Mohammed SH, et al. Large vessel thrombosis in patient with COVID-19, a case series. *Ann Med Surg (Lond.)* 2020;**60**:526–30.
- 40 Fournier M, Faille D, Dossier An, Mageau A, Roland PN, Ajzenberg N, et al. Arterial thrombotic events in adult inpatients with COVID-19. *Mayo Clin Proc* 2021;**96**:295–303.
- 41 Baccellieri D, Bilman V, Apruzzi L, Monaco F, D'Angelo A, Loschi D, et al. A case of COVID-19 patient with acute limb ischemia and heparin resistance. *Ann Vasc Surg* 2020;**68**:88.
- 42 Inspiration Investigators. Effect of intermediate-dose vs standard-dose prophylactic anticoagulation on thrombotic events, extracorporeal membrane oxygenation treatment, or mortality among patients with COVID-19 admitted to the intensive care unit: the INSPIRATION Randomized Clinical Trial. *JAMA* 2021;**325**:1620–30.
- 43 Parisi R, Costanzo S, Di Castelnuovo A, de Gaetano G, Donati MB, Iacoviello L. Different anticoagulant regimens, mortality, and bleeding in hospitalized patients with COVID-19: a systematic review and an updated meta-analysis. *Semin Thromb Hemost* 2021;**47**:372–91.
- 44 Bellosta R, Luzzani L, Natalini G, Pegorer MA, Attisani L, Cossu LG, et al. Acute limb ischemia in patients with COVID-19 pneumonia. *J Vasc Surg* 2020;**72**:1864–72.
- 45 Dragas M, Zlatanovic P, Koncar I, Ilic N, Radmili O, Savic N, et al. Effect of intra-operative intra-arterial thrombolysis on long term clinical outcomes in patients with acute popliteal artery aneurysm thrombosis. *Eur J Vasc Endovasc Surg* 2020;**59**:255–64.
- 46 Lie SA, Wong SW, Wong LT, Wong TG, Chong SY. Practical considerations for performing regional anesthesia: lessons learned from the COVID-19 pandemic. *Can J Anaesth* 2020;**67**:885–92.
- 47 Aasen M, Blecha M. Percutaneous revascularization for COVID-19 induced spontaneous arterial thrombosis. *Vasc Endovascular Surg* 2021. doi: 10.1177/15385744211010445 [Epub ahead of print].
- 48 Maurera AH, Vu JH, Rehring TF, Layman PF, Johnson SP. Acute limb ischemia in minimally symptomatic SARS-CoV-2 infection. *J Vasc Interv Radiol* 2020;**31**:2150–3.
- 49 Muhammad K, Tantawy TG, Makar RR, Olojugba O. Successful catheter-directed thrombolysis for acute lower limb ischemia secondary to COVID-19 infection. *Ann Vasc Surg* 2021;**71**:103–11.
- 50 Vacirca A, Faggioli G, Pini R, Teutonico P, Pilato A, Gargiulo M. Unheralded lower limb threatening ischemia in a COVID-19 patient. *Int J Infect Dis* 2020;**96**:590–2.
- 51 Horani G, Kaur K, Patel P, Virk H, Shamoof F. Acute limb ischemia as the initial severe presentation in COVID-19. *Cureus* 2021;**13**:e14226.
- 52 Pasqui E, de Donato G, Brancaccio B, Casilli G, Ferrante G, Palasciano G. Misdiagnosed acute limb ischemia in three nonhospitalized patients recovering from a nonsevere COVID-19 infection. *Ann Vasc Surg* 2021. doi: 10.1016/j.avsg.2021.04.029 [Epub ahead of print].
- 53 Singh B, Kaur P, Patel P, Nabati C, Ayad S, Shamoof F, Maroules M. COVID-19 and arterial thrombosis: report of 2 cases. *Radiol Case Rep* 2021;**16**:1603–7.
- 54 Erkul GSA, Erkul S, Parlar AI, Cekirdekci A. A probable Covid-19 case presented with acute upper limb ischemia. *Ann Vasc Surg* 2021. doi: 10.1016/j.avsg.2021.05.003 [Epub ahead of print].

- 55 de Donato G, Pasqui E, Sponza M, Intriери F, Spinazzola A, Silingardi R, et al. Safety and efficacy of vacuum assisted thrombo-aspiration in patients with acute lower limb ischaemia: the INDIAN Trial. *Eur J Vasc Endovasc Surg* 2021;**61**:820–82.
- 56 Benson RA, Nandhra S. Outcomes of vascular and endovascular interventions performed during the coronavirus disease 2019 (COVID-19) pandemic. *Ann Surg* 2021;**273**:630–5.
- 57 Behrendt C-A, Seiffert M, Gerloff C, L'Hoest H, Acar L, Thomalla G. How does SARS-CoV-2 infection affect survival of emergency cardiovascular patients? A cohort study from a German insurance claims database. *Eur J Vasc Endovasc Surg* 2021;**62**:119–25.
- 58 Indes JE, Koleilat I, Hatch AN, Choinski K, Jones DB, Aldailami H, et al. Early experience with arterial thromboembolic complications in patients with COVID-19. *J Vasc Surg* 2021;**73**:381–9.
- 59 Ilonzo N, Ralosaao A, Safir S, Vouyouka A, Phair J, Baldwin M, et al. Acute thrombotic manifestations of coronavirus disease 2019 infection: Experience at a large New York City health care system. *J Vasc Surg* 2021;**73**:789–96.
- 60 Makhoul K, Shukha Y, Hanna LA, Nitecki S, Leiderman M, Hayek T, et al. A case of rapidly progressive upper limb ischemic necrosis in a patient with COVID-19. *Int J Infect Dis* 2021;**106**:401–4.
- 61 Galanis N, Stavrika C, Agathangelidis F, Petsatodis E, Giakoulouf C, Givissis P. Coagulopathy in COVID-19 infection: a case of acute upper limb ischemia. *J Surg Case Rep* 2020;**2020**:rjaa204.
- 62 Schultz K, Wolf JM. Digital ischemia in COVID-19 patients: case report. *J Hand Surg Am* 2020;**45**:518–22.
- 63 Kaur P, Qaqa F, Ramahi A, Shamoony Y, Singhal M, Shamoony F, et al. Acute upper limb ischemia in a patient with COVID-19. *Hematol Oncol Stem Cell Ther* 2020. doi: 10.1016/j.hemonc.2020.05.001 [Epub ahead of print].
- 64 Shao T, In-Bok Lee C, Jabori S, Rey J, Duran ER, Kang N. Acute upper limb ischemia as the first manifestation in a patient with COVID-19. *J Vasc Surg Cases Innov Tech* 2020;**6**:674–7.
- 65 Alosaimi R, Albajri A, Albalwi RM. Acute upper limb ischemia in a patient with COVID-19 pneumonia. *Clin Med Rev Case Rep* 2020;**7**:317.
- 66 Bilge A, Karasoy İ, Neziroğlu E, Güner Y. Upper extremity arterial thromboembolism in a patient with severe COVID-19 pneumonia: a case report. *Jt Dis Relat Surg* 2021;**32**:551–5.
- 67 Gonzalez-Fajardo JA, Ansuategui M, Romero C, Comanges A, Gómez-Arbeláez D, Ibarra G, et al. Mortality of covid-19 patients with vascular thrombotic complications. *Med Clin (Barc)* 2021;**156**:112–7.
- 68 Mascia D, Kahlberg A, Melloni A, Rinaldi E, Melissano G, Chiesa R. Single-center vascular hub experience after 7 weeks of COVID-19 pandemic in Lombardy (Italy). *Ann Vasc Surg* 2020;**69**:90–9.