

Sciatic Nerve High Division: Two Different Anatomical Variants



Divisão Alta do Nervo Isquiático: Duas Variantes Anatômicas Distintas

Diogo PAIS¹, Diogo CASAL¹, Maria Alexandre BETTENCOURT PIRES¹, Andrea FURTADO², Tiago BILHIM², Maria ANGÉLICA-ALMEIDA³, João GOYRI-O'NEILL¹
Acta Med Port 2013 May-Jun;26(3):208-211

ABSTRACT

Introduction: Sciatic nerve variations are relatively common. These variations are often very significant in several fields of Medicine. The purpose of this paper is to present two such variants and discuss their clinical implications.

Material and Methods: Three Caucasian cadavers with no prior history of lower limb trauma or surgery were dissected and found to present anatomical variants of the sciatic nerve.

Results: In all cases the sciatic nerve divided above the popliteal fossa. In two cases (cadavers 1 and 2) it divided on both sides in the inferior portion of the gluteal region in its two terminal branches: the common fibular and the tibial nerves. In another case (cadaver 3) the sciatic nerve was found to divide inside the pelvis just before coursing the greater sciatic notch. The common fibular nerve exited the pelvis above the piriformis muscle and then passed along its posterior aspect, while the tibial nerve coursed deep to the piriformis muscle.

Discussion: According to the literature, the anatomical variant described in cadaver 3 is considered relatively rare. This variant can predispose to nerve entrapment and thus to the piriformis syndrome, sciatica and coccygodynia. The high division of the sciatic nerve, as presented in cadavers 1 and 2, can make popliteal nerve blocks partially ineffective.

Conclusion: The anatomical variants associated with a high division of the sciatic nerve, must always be born in mind, as they are relatively prevalent, and have important clinical implications, namely in Anesthesiology, Neurology, Sports Medicine and Surgery.

Keywords: Sciatic Nerve/anatomy and histology.

RESUMO

Introdução: As variações do nervo isquiático são relativamente comuns e frequentemente muito significativas clinicamente. O objetivo deste trabalho é apresentar duas destas variações e discutir algumas das suas implicações clínicas.

Material e Métodos: Três cadáveres caucasianos sem história prévia de trauma ou cirurgia no membro inferior foram dissecados, apresentando variações anatômicas do nervo isquiático.

Resultados: Em todos os casos o nervo isquiático dividia-se acima da fossa poplíteia. Em dois casos (cadáveres 1 e 2) a terminação deste nervo ocorria na porção inferior da região glútea nos seus dois ramos terminais: os nervos fibular comum e tibial. Num outro caso (cadáver 3), o nervo isquiático dividia-se ainda dentro da bacia antes de percorrer a incisura isquiática maior. Neste caso, o nervo fibular comum saía da pelve acima do músculo piriforme, passando em seguida ao longo de sua face posterior, enquanto que o nervo tibial corria profundamente ao músculo piriforme.

Discussão: De acordo com a literatura, a variante anatômica descrita no cadáver 3 é considerada relativamente rara. Esta variante poderá predispor a síndromes compressivas do nervo isquiático. A divisão alta do nervo isquiático, de que são exemplos os cadáveres 1 e 2, pode comprometer a eficácia dos bloqueios anestésicos ao nível da fossa poplíteia.

Conclusão: As variantes anatômicas associadas à divisão alta do nervo isquiático devem sempre ser tidas em consideração por serem relativamente comuns e terem importantes implicações clínicas, nomeadamente nas áreas de Anestesiologia, Neurologia, Medicina do Desporto e Cirurgia.

Palavras-chave: Nervo Isquiático/Anatomia.

INTRODUCTION

The sciatic nerve is the thickest and the longest nerve in the human body.¹ Therefore, it is often approached in the clinical setting, either in the context of trauma, tumors, vascular lesions in neighborhood structures, entrapment syndromes, hip or femur surgery or percutaneously for lower limb anesthetic blocks.¹⁻⁴ Hence, a detailed knowledge of the normal anatomy of this nerve, as well of its potential anatomical variants is of paramount importance.¹⁻⁵

The importance of this subject was in fact recognized as early as the 16th century by Ambroise Paré. Paré described in detail the sciatic nerve. However, he failed to recognize most of the variations it could present.⁶ This limitation was

addressed later on by numerous authors. Cruveilhier, for example, in the 19th century recognized that the sciatic nerve could divide anywhere from the sacral plexus to the popliteal fossa.⁷ At the end of the 19th century, Testut had already divided the numerous variations of the sciatic nerve reported to date in 4 types.⁸

Since then, many papers have been published on the anatomical variations of the sciatic nerve and their clinical significance in a wide range of medical disciplines.⁹ However, most clinicians, including surgeons, do not have the opportunity to see many of these variants of the sciatic nerve, as medical procedures, even surgical ones, are increasing-

1. Anatomy Department. Medical Sciences Faculty. New University of Lisbon. Lisbon. Portugal.

2. Department of Radiology. São José Hospital. Lisbon. Portugal.

3. Plastic and Reconstructive Surgery Department and Burn Unit. São José Hospital. Lisbon. Portugal.

Recebido: 23 de Novembro de 2012 - Aceite: 22 de Janeiro de 2013 | Copyright © Ordem dos Médicos 2013

ly less invasive, and therefore are associated with a limited view of the vascular and nerve structures. In this paper we present two variants of the sciatic nerve with important clinical implications in three different cadavers.

MATERIAL AND METHODS

Three different female cadavers, of Caucasian origin, were carefully dissected from the gluteal region to the foot at our institution. Death had occurred at 79, 81 and 85 years of age. None of the cadavers had an history of previous lower limb trauma or surgery.

Anatomical variations of the sciatic nerve were observed and photographed.

RESULTS

In all cadavers a high division of the sciatic nerve was noted (Fig.s 1 to 3).

In two cadavers (cadavers 1 and 2) the sciatic nerve divided bilaterally in its terminal branches, the tibial and the

common fibular nerve, in the inferior portion of the gluteal region (Fig.s 1A, 1B). The nerve branches for the muscles of the posterior compartment of the thigh were almost all derived from the medial branch of division of the sciatic nerve, that is to say from the tibial nerve. The exception was the short head of the biceps femoris which was innervated by the common fibular nerve. From the popliteal fossa downwards the common fibular nerve and the tibial nerve had a path identical to what is generally reported.^{1,9,10}

In another cadaver (cadaver 3) the sciatic nerve divided, on both sides, in its terminal branches inside the pelvis, the tibial and the common fibular nerve, just before crossing the greater sciatic notch (Fig.s 2, 3). The common fibular nerve exited the pelvis above the piriformis muscle and then passed along its posterior aspect, while the tibial nerve coursed deep to the piriformis muscle. The nerve supply of the posterior thigh muscles was derived from the two terminal branches of the sciatic nerve, in a manner identical to that described above. Below the knee, the common fibular

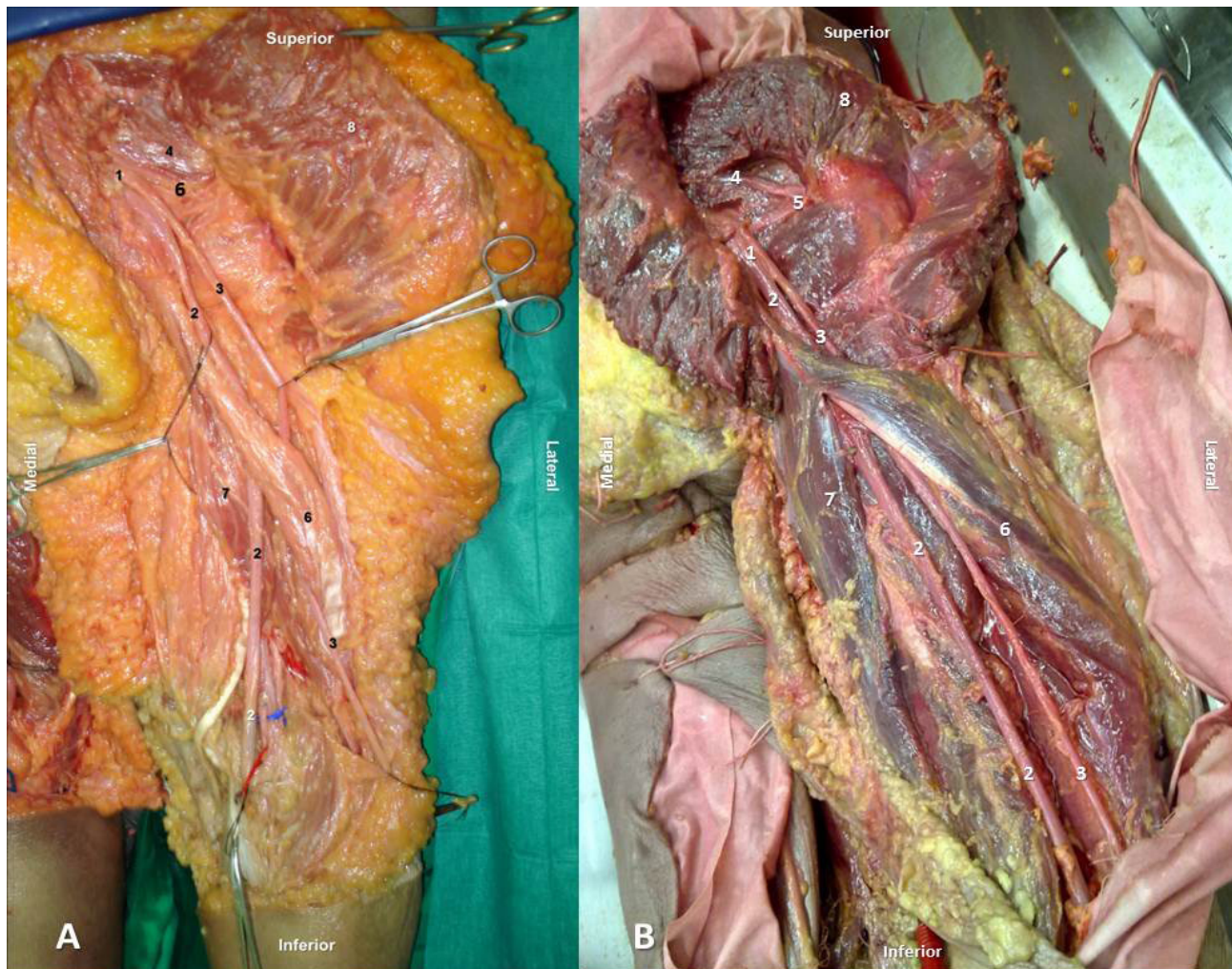


Figure 1 – Dissection of the posterior aspect of the left thigh and gluteal regions in two distinct cadavers (A and B) showing a high division of the sciatic nerve. The sciatic nerve divided in its terminal branches, the tibial and the common fibular nerve, in the inferior portion of the gluteal region.

The nerve branches for the muscles of the posterior compartment of the thigh were almost all derived from the medial branch of division of the sciatic nerve, that is to say from the tibial nerve. The exception was the short head of the biceps femoris which was innervated by the common fibular nerve.

1- Sciatic nerve; 2- Tibial Nerve; 3- Common fibular nerve; 4- Piriformis muscle; 5- Inferior gluteal nerve; 6- Long head of the biceps femoris muscle; 7- Semitendinosus muscle; 8- Gluteus maximus muscle.

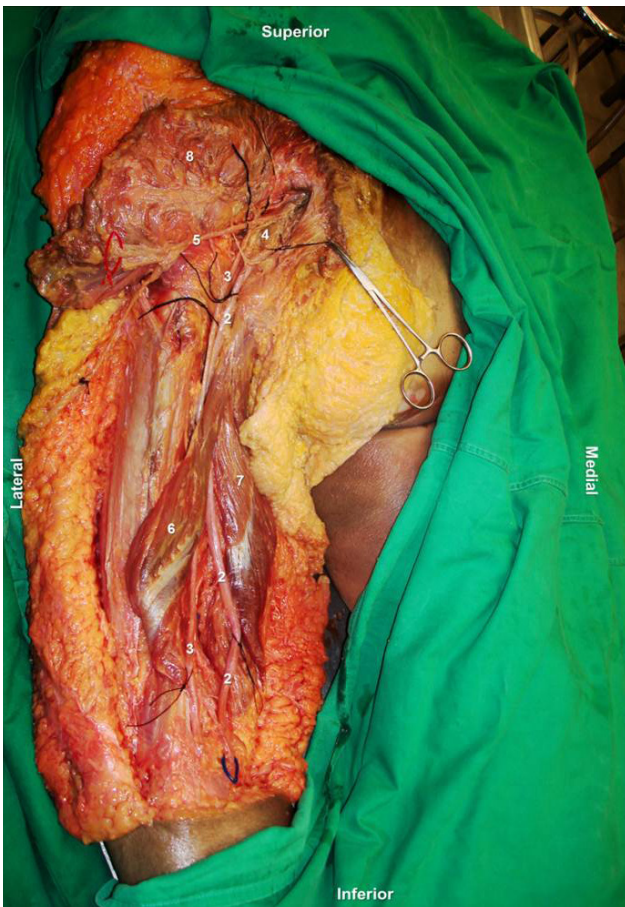


Figure 2 – Dissection of the posterior aspect of the left thigh and gluteal regions showing a high division of the sciatic nerve. The sciatic nerve divided in the tibial and common fibular nerve just before crossing the greater sciatic notch.

1- Sciatic nerve; 2- Tibial Nerve; 3- Common fibular nerve; 4- Pyriformis muscle; 5- Inferior gluteal nerve; 6- Long head of the biceps femoris muscle; 7- Semitendinosus muscle; 8- Gluteus maximus muscle

nerve and the tibial nerve had a regular path and distribution.^{1,9,10}

DISCUSSION

Although the anatomical variants of the sciatic nerve herein described have been previously reported by other authors, they are considered relatively rare. In fact, it has been repeatedly shown that the sciatic nerve may divide in its terminal branches from its origin in the pelvic region until the popliteal fossa. There are numerous reports in the literature of terminal division of the sciatic nerve in almost every point between these two anatomical regions.²⁻⁴

In most cases, the sciatic nerve courses the anterior surface of the pyriformis muscle undivided, to branch into its terminal divisions at the upper angle of the popliteal fossa or in the thigh above this angle.^{1,4} The frequency of this pattern of division of the sciatic nerve ranges from 70 to 85% in most series.^{1,4}

In up to 20% of cases, the sciatic nerve can present a division above this point, that is to say a high division, as we describe in cadavers 1 to 3.^{1,4} However, the specific variant encountered in cadaver 3 is relatively rare. This variant, in which the sciatic nerve gives off its terminal branches

above the pyriformis, one branch exiting the pelvis above the muscle and subsequently passing along its posterior aspect, while the second courses deep to the pyriformis muscle, is even disavowed by some authors.^{1,4} The highest incidence of this variant was reported by Pokorný et al. who in 91 cadaveric dissections found it in only 4.4% of cases.^{4,11-13} The first description of this variant is attributed to Sappey.¹¹ Interestingly, Cruveilhier, Testut and Le Double, for example, also alluded to this variant in their classical anatomy textbooks.^{4,7,14,15}

However, many more variants of the high division pattern of the sciatic nerve are described in the literature. A recent systematic review and metanalysis of the anatomical variants of the sciatic nerve in its path close to the pyriformis muscle that reviewed 18 studies, corresponding to a pool of 6 062 cadavers, found anatomical variants in 16.9% of cases, suggesting that this region is particularly prone to variation.⁹

There is a wide consensus in the literature that the numerous variants of the sciatic nerve most likely result from a stochastic process of separation of the primitive elements of the sciatic nerve.^{4,11-13,16} In fact, the lower limb bud is initially associated with the primitive lumbar and sacral plexuses.¹⁶ As the limb elongates and widens, the nervous elements are drawn distally and are separated into dorsal and ventral components, distributed into the developing anterior and posterior muscles and overlying integument.^{1,16} The sciatic nerve in particular results from the parallel development of the dorsal and ventral components of the growing sacral plexus, that will ultimately originate the common fibular nerve and the tibial nerve, respectively. These two nerves become joined for a variable length in the definitive form, as they grow caudally and ventrally together in the developing lower limb.¹ As result, in the definitive form, the sciatic nerve can divide in its terminal branches in either the pelvis, as we observed in cadaver 3, in the gluteal region, as recorded in cadavers 1 and 2, or in the posterior thigh or the popliteal

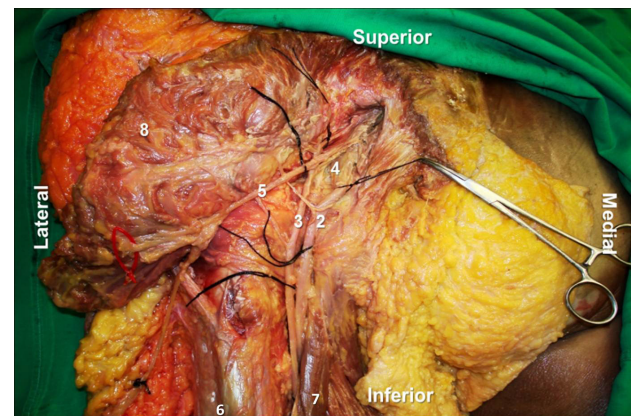


Figure 3 – Dissection of the posterior aspect of the left thigh and gluteal regions showing a high division of the sciatic nerve and an aberrant path of one of its branches.

The sciatic nerve divided in its terminal branches, the tibial and the common fibular nerve, before crossing the greater sciatic notch. The common fibular nerve exited the pelvis above the pyriformis muscle and then passed along its posterior aspect, while the tibial nerve coursed deep to the pyriformis muscle.

Sciatic nerve; 2- Tibial Nerve; 3- Common fibular nerve; 4- Pyriformis muscle; 5- Inferior gluteal nerve; 6- Long head of the biceps femoris muscle; 7- Semitendinosus muscle; 8- Gluteus maximus muscle

fossa, as it is most common.¹

The anatomical variants described in this paper have important clinical implications. The division of the sciatic nerve above the popliteal fossa, for example, can result in failure of the sciatic nerve anesthetic block while attempting popliteal nerve block.¹ Additionally, an high division of the sciatic nerve can result in involvement of only one of the two terminal branches of this nerve in sciatic neuropathy, giving rise to atypical sciatic compressive syndromes.¹ Furthermore, the course over and below the piriformis muscle of the two terminal divisions of the sciatic nerve, as it was observed in cadaver 3, can make nerve entrapment more likely, thus potentially predisposing to the piriformis syndrome, sciatica and coccygodynia.^{1-3,5,17-19}

CONCLUSION

The anatomical variants associated with the division of the sciatic nerve in the proximal aspect of the lower limb, including its division above the piriformis muscle, must al-

ways be born in mind, as they are relatively prevalent, and have important clinical implications, namely in Anesthesiology, Neurology, Sports Medicine and Surgery.^{2,3,5,17-19}

ACKNOWLEDGMENTS

The authors are grateful to all Technical Staff members of the Department of Anatomy, in particular to Carlos Lopes and to Marco Costa.

CONFLICT OF INTEREST

The authors declare that they do not have any conflicts of interest in concern to this article.

FUNDING SOURCES

Diogo Casal, one of the authors, received a scholarship from the Programme for Advanced Medical Education sponsored by Fundação Calouste Gulbenkian, Fundação Champalimaud, Ministério da Saúde and Fundação para a Ciência e Tecnologia, Portugal.

REFERENCES

1. Prakash, Bhardwaj AK, Devi MN, Sridevi NS, Rao PK, Singh G. Sciatic nerve division: a cadaver study in the Indian population and review of the literature. *Singapore Med J.* 2010;51:721-3.
2. Schwemmer U, Markus CK, Greim CA, Brederlau J, Trautner H, Roewer N. Sonographic imaging of the sciatic nerve and its division in the popliteal fossa in children. *Paediatr Anaesth.* 2004;14:1005-8.
3. Schwemmer U, Markus CK, Greim CA, Brederlau J, Kredel M, Roewer N. Sonographic imaging of the sciatic nerve division in the popliteal fossa. *Ultraschall Med.* 2005;26:496-500.
4. Pokorny D, Jahoda D, Veigl D, Pinskerova V, Sosna A. Topographic variations of the relationship of the sciatic nerve and the piriformis muscle and its relevance to palsy after total hip arthroplasty. *Surg Radiol Anat.* 2006;28:88-91.
5. McCrory P, Bell S. Nerve entrapment syndromes as a cause of pain in the hip, groin and buttock. *Sports Med.* 1999;27:261-74.
6. Paré A. Le Sixieme Livre De l'Anatomie. In: Buon G, editor. *Oeuvres d'Ambroise Paré de la Val du Maine.* 4ème ed. Paris;1585. p.222.
7. Cruveilhier J. *Traité d'Anatomie Descriptive.* In: *Angéologie et Névrologie.* 4ème ed. Paris: Asselin et Labé; 1871. p.652.
8. Testut L. *Névrologie: Système Nerveux Périphérique.* In: *Traité d'Anatomie Humaine.* 4ème ed. Doin; 1899. p.27-8.
9. Small NR. Variations of the piriformis and sciatic nerve with clinical consequence: a review. *Clin Anat.* 2010;23:8-17.
10. Benzon HT, Katz JA, Benzon HA, Iqbal MS. Piriformis syndrome: anatomic considerations, a new injection technique, and a review of the literature. *Anesthesiology.* 2003;98:1442-8.
11. Pecina M. Contribution to the etiological explanation of the piriformis syndrome. *Acta Anat.* 1979;105:181-7.
12. Beaton LE. The relation of the sciatic nerve and of its subdivisions to the piriformis muscle. *Anat Rec.* 1937;70:1-5.
13. Mouret J. *Rapports des muscles pyramidaux avec le nerf sciatique.* *Montpél Med.* 1893;2:230-3.
14. Testut L. *Les anomalies musculaires chez l'homme.* Paris: Masson; 1884.
15. Le-Double AF. *Traité des variations du système musculaire de l'homme.* Paris; 1897.
16. Davut O, Yakup G, Sevgi B, Senoglu M, Kalender AM, Calik M. The topographical features and variations of nervus ischiadicus in human fetuses. *Bratisl Lek Listy.* 2011;112:475-8.
17. Austin MS, Klein GR, Sharkey PF, Hozack WJ, Rothman RH. Late sciatic nerve palsy caused by hematoma after primary total hip arthroplasty. *J Arthropl.* 2004;19:790-2.
18. May O, Girard J, Hurtevent JF, Migaud H. Delayed, transient sciatic nerve palsy after primary cementless hip arthroplasty: a report of two cases. *J Bone Joint Surg Br.* 2008;90:674-6.
19. De Luca CJ, Bloom LJ, Gilmore LD. Compression induced damage on in-situ severed and intact nerves. *Orthopedics.* 1987;10:777-84.